


DIONavi. Clinical Case Report Ver.3

Product Introduction : DIONavi.


Clinical Case Report



Evolved for Precision and Stability

-
-
-

Digital Navigation Implant **DIO**navi.





W H Y

DIGITAL
IMPLANT

DIONAVI.



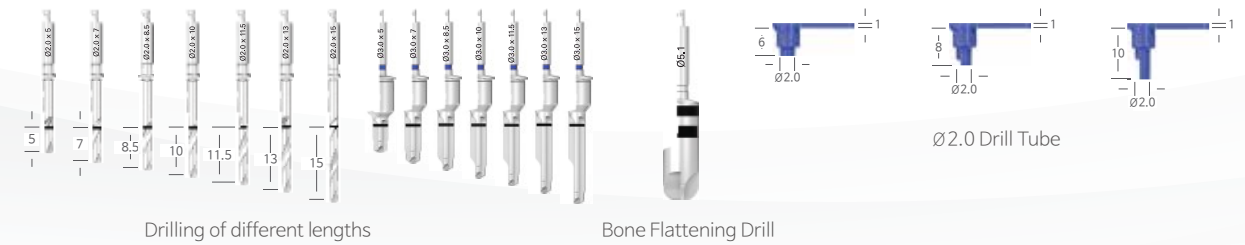

DIONavi. digital implant is different!

Fully Digitalization_ DIONavi.

STRONG SAFETY

- Drilling of different lengths - Accuracy + Safety UP & Slip prevention tool



- Low speed drilling and stepwise injection (prevents bone heating)

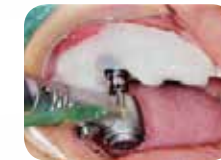50RPM

Heat reduced by low speed drilling, noise reduced by no injection



Prevents bone heating and removes particles in bone cavity by injection in each drill stop (after removal of drill)

- Easily secures sight of operator by no injection while drilling and low speed drilling



VS



HIGH ACCURACY

- Removes inconvenience and error of analog method

SCAN > DESIGN > MANUFACTURE > PRODUCT

- Digitalization of all processes from Input Data to Output Product

- DIONavi.Full Digital Leveling Error : Average 0.26°

* Journal of Korean Academy of Prosthodontics
- Accuracy assessment of implant placement using a stereolithographic surgical guide made with digital scan, 2015, Professor Seung-Mi Jeong

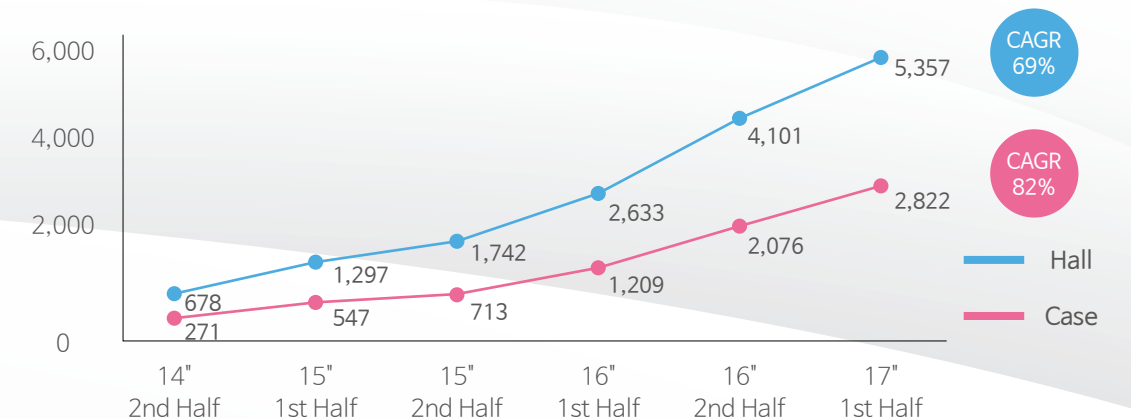
DIVERSE INDICATION

- Provides perfect solutions to different cases


Edentulous | Edentulous | Sinus lift | Metal artifact |
 Immediate implantation after tooth extraction Case with narrow bones |
 Case with narrow interdental space | Posterior region with small mouth opening |
 Free end case | Prosthetics applied immediately after implantation on low bone level

VERIFYING GUIDE SYSTEM

Usage trend (monthly average) of DIONavi.



Digital Implant DIONavi.
LINE-UP DIONavi.



Fixture Size	Narrow			Regular				Wide		
DIONavi. Sleeve Size	Narrow			Standard				Wide		
	3.0	3.3	3.8	4.0	4.5	5.0	5.5	6.0	6.5	7.0



Standard Case

DIONavi. Master Kit
Off-Set height : 9 / 10.5 / 12mm

[CODE : UF 05]



Wide Case

DIONavi. Wide Kit
Case with small mouth opening / Case with posterior region
Off-Set height : 8 / 9.5mm

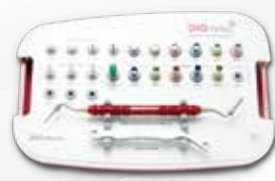[CODE : UF 11]



Narrow Case

DIONavi. Narrow Kit
Case with narrow bones / Case with narrow interdental space
Off-Set height : 12mm

[CODE : UF 14]



Sinus Case

DIONavi. Master Kit & DIONavi. Sinus Crestal Approach Kit
Hydraulic sinus lifting kit

[CODE : SMK 02]



Edentulous Case

DIONavi. Master Kit & DIONavi. Special Kit
Free end case / Case of immediate implantation after tooth extraction
Including 15mm final drill

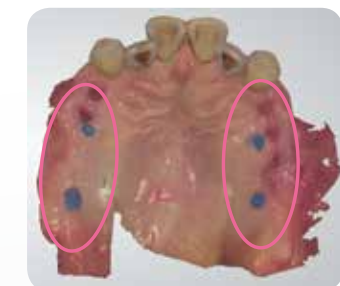[CODE : SGF 02]

Digital Implant DIONavi.
PATENTED SOLUTIONS DIONavi.

- Metal Artifact**
Difficulty of data matching due to CT scattering
- Free End Case**
Difficulty of matching implant site / Difficulty of bite taking
- Edentulous Case**
Use of half-digital with plaster case because of no data matching (reduced accuracy)

Image	Name
	Marker CODE : SGM 5040
	Flow resin (radiopacity) (CHARMFIL BLUE resin recommended) CODE : ORCFFB 01

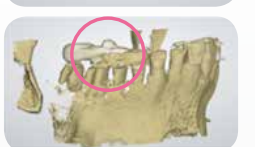When attaching marker
It can be attached easily by using medical adhesive (Histoacryl) CODE : 1050060 and flow resin (Charmfil).



< Free End



Metal Artifact >



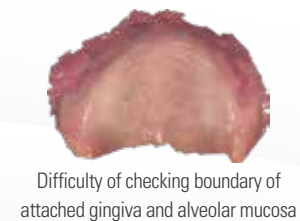Scan Retractor

Fully Digitalization Workflow for Edentulous Case

Upper jaw

Lower jaw

Before using scan retractor



Difficulty of checking boundary of attached gingiva and alveolar mucosa



Cannot use oral scan due to movement of tongue

After using scan retractor



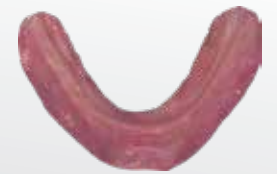Upper jaw
CODE : SCANR 01S




Lower jaw
CODE : SCANR 02S




Accurate recognition of upper jaw opening, control of tongue movement (lower jaw), reference point of oral scan





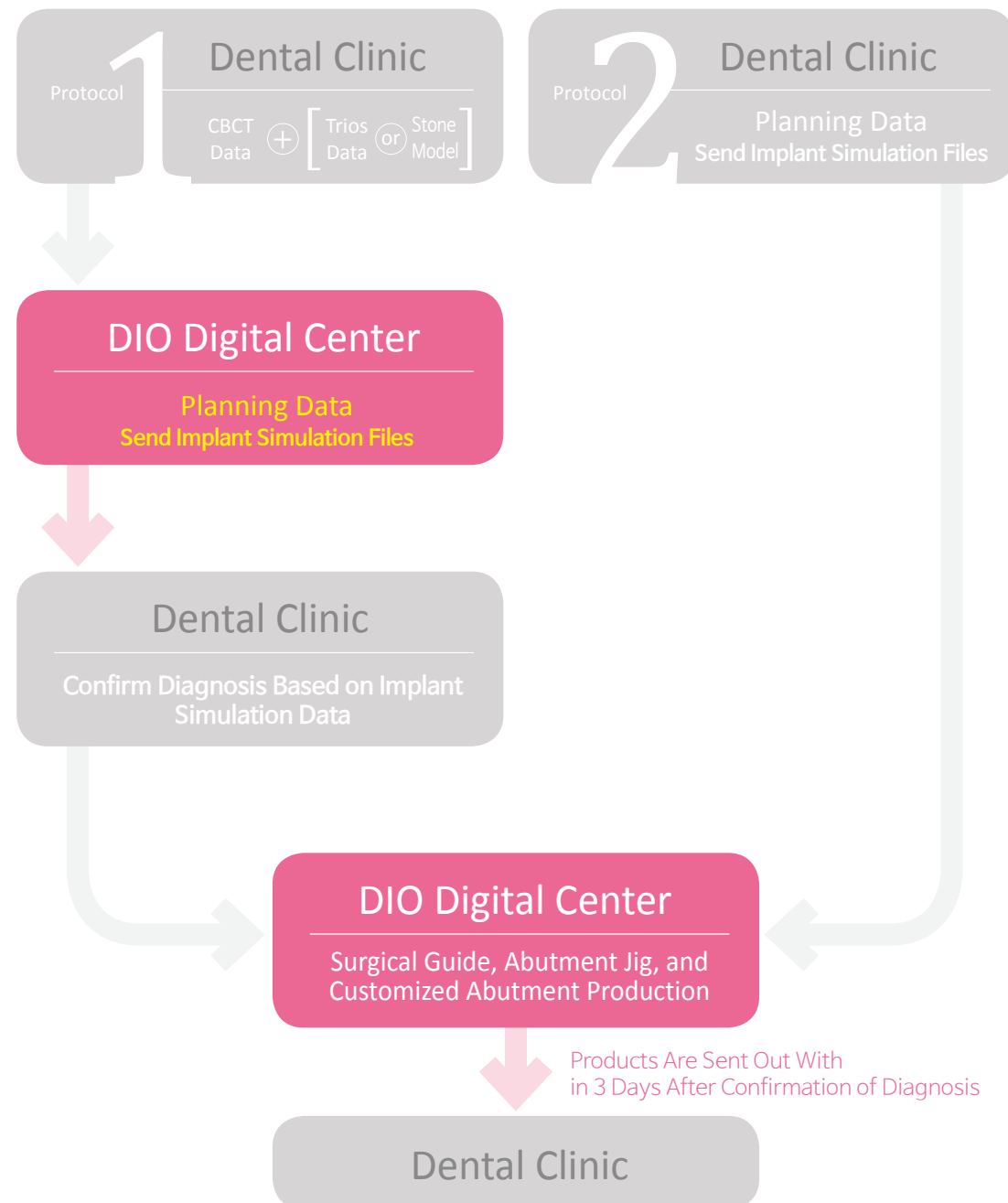
At the Planned
Location
Perfect Implant
Planning



One-Step Protocol

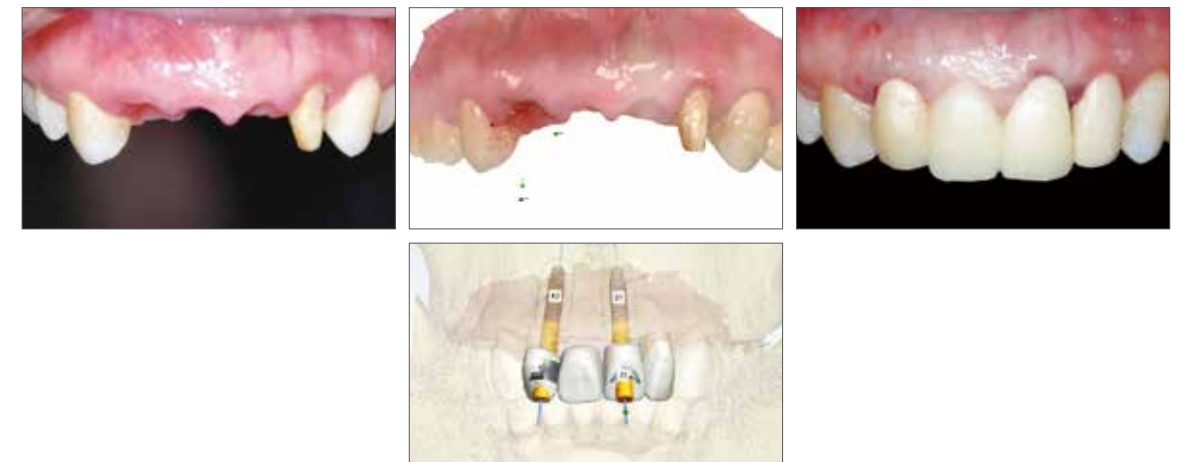After sending the CBCT and intra-oral Scan Data, it will take about seven (7) days to fabricate the Surgical Guide using the 3D printer.

※ For edentulous cases that require splint a separate inquiry is required.



DIONavi.System

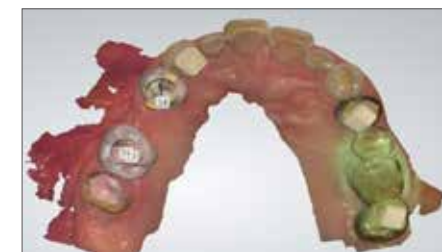Digital Navigation Implant System DIONavi., using 100% digital data, provides the optimal process to a successful treatment prior to a scheduled implant surgery. Especially with DIONavi. Surgical Kit, the surgeon can achieve results that exactly match treatment planning with added convenience and high precision. In addition, patients will experience higher than expected level of comfort.



Highest Precision and Stability

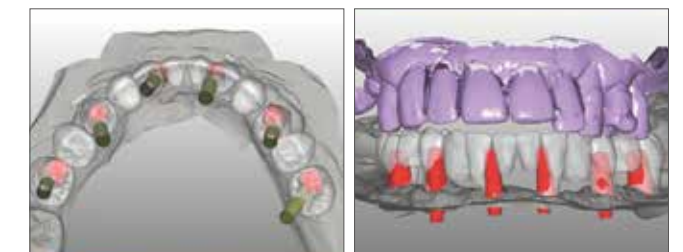
DIONavi offers the ability to consider occlusion and stress distribution during implant planning and increases the accuracy of implant surgery. In addition, high quality patient consultation can be conducted through 3D simulation.

DIONavi Surgery




Due to accurate pre-designed positioning of the Crown, the Fixture right below can withstand maximum loading conditions.



Traditional Implant Surgery




Due to difficulty in centrally aligning both implant and crown so as to effectively distribute loading, prosthetic fracture and implant failure may arise.



At the Planned
Location
Perfect Implant
Planning



DIO navi
CLINICAL
CASE
REPORT

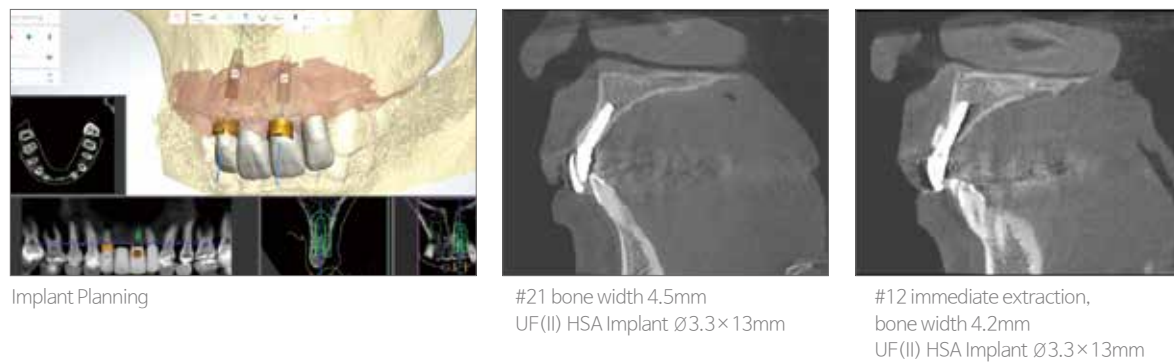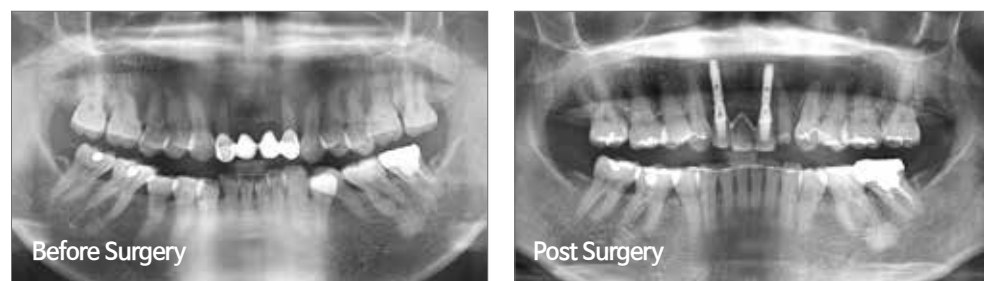


Minimally invasive implant placement using DIONavi. surgery

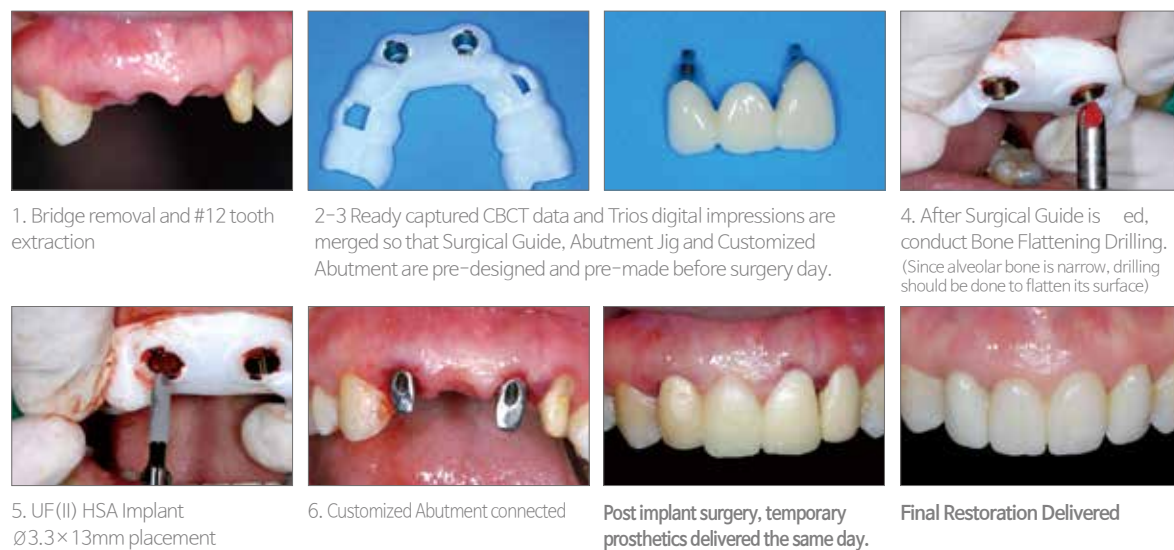
Dr. Kang JaeSeok, Clinical Director at Yedam Dental Clinic

49 year old female with maxillary anterior bridge. Surviving bone is insufficient and implant surgery appears doubtful. For aesthetic reasons planned temporary prosthetics.

#12 tooth extraction and immediate temporary prosthetics | bone width 4.2mm → UF(II) Narrow Ø3.3 Fixture Placement.
#21 post placement mount temporary prosthetics | bone width 4.5mm → UF(II) Narrow Ø3.3 Fixture Placement.



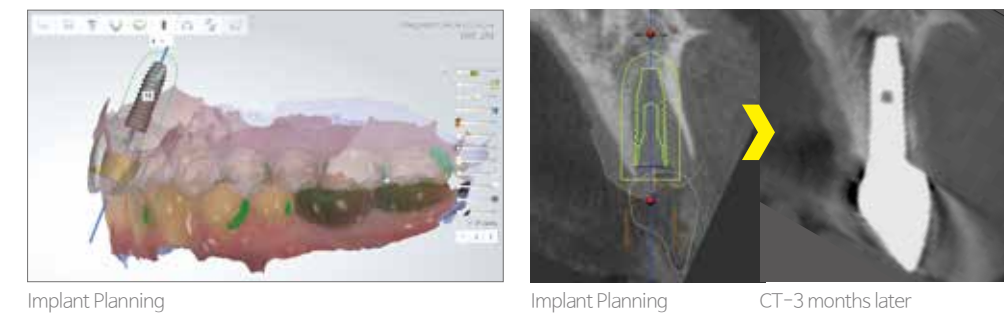
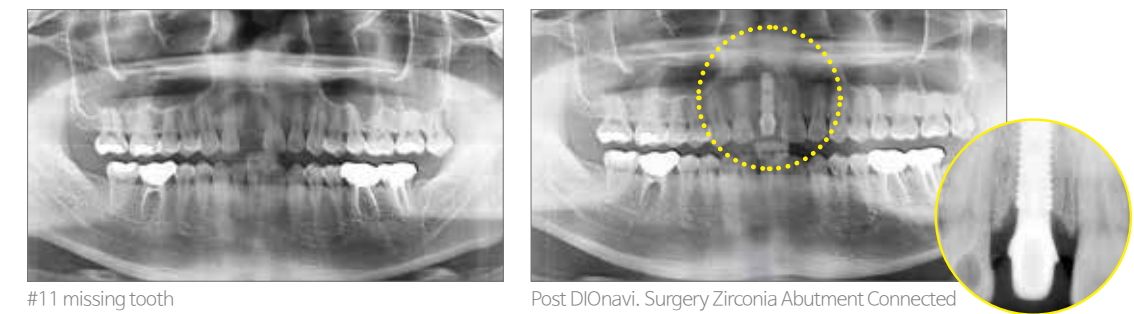
DIONavi. Surgical Procedure



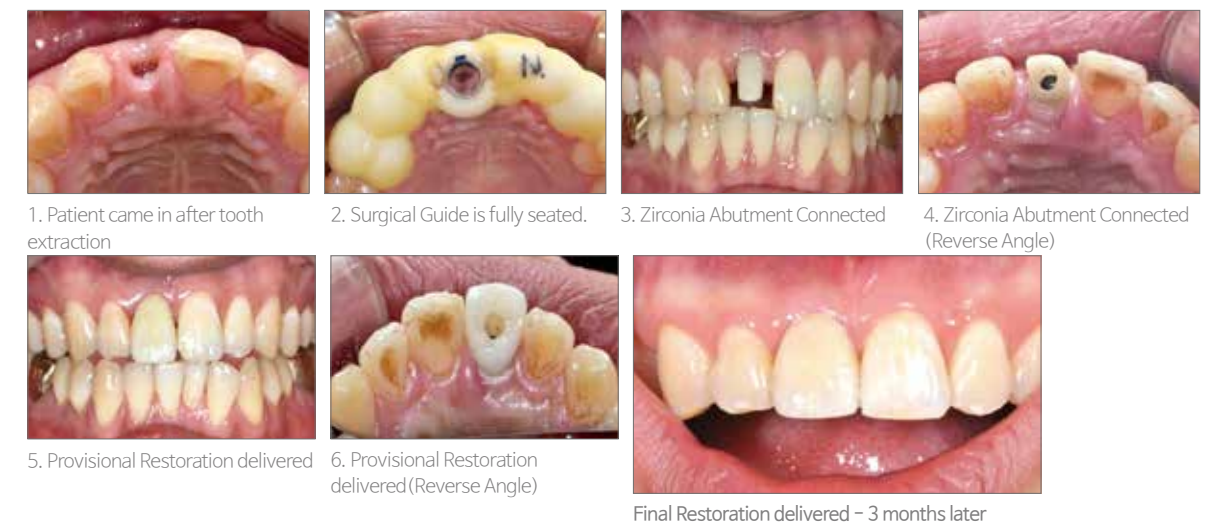Through Advance Planning Expand the Limits of Implant Surgery at the Maxillary Anterior Region

Dr. Dong DoEun, Clinical Director, Welcome Dental – Mampo Branch

After placement of HF(II) HSA Implant, labially use Bio-Oss for GBR procedure



DIONavi. Surgical Procedure

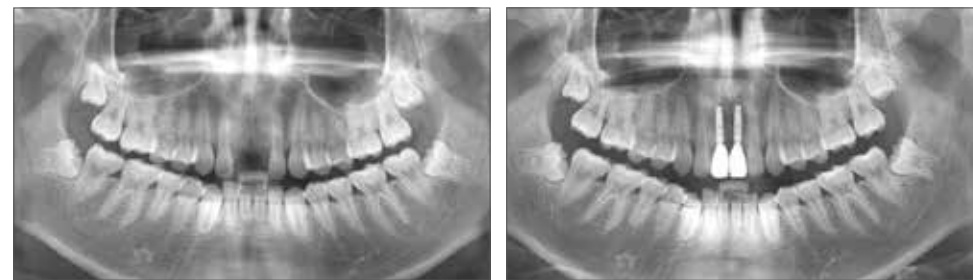


Esthetic Zone Implant Restorations of Maxillary Incisors Using CBCT- Surgical Guide

Choi SungOk, Clinical Director, Apple Tree Dental Hospital

17 year old, male / Under went clinical procedure for esthetic implant restoration. This is the restoration of lost maxillary central incisors as well as production of aesthetically shaped prosthetics.

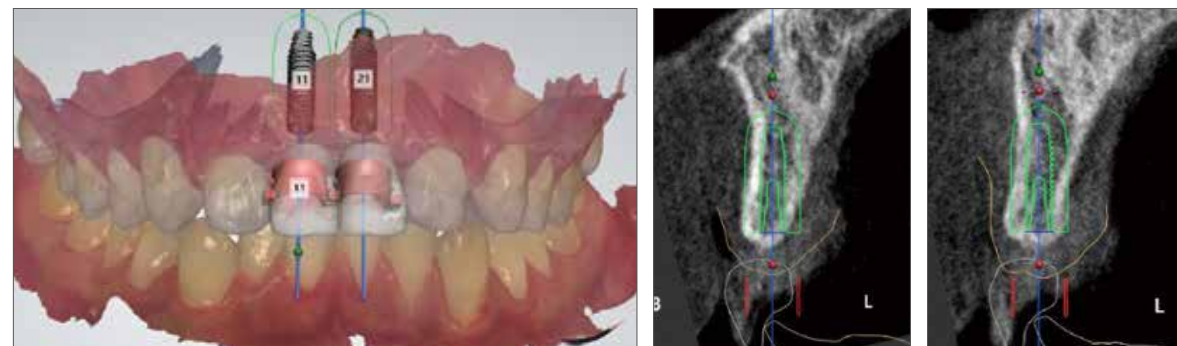Implant Restoration treatment for the narrow maxillary central incisor is a high difficulty level surgery. During which CBCT Data and Intra-oral scan are used to produce precise Surgical Guide to be used to conduct accurate and safe surgery and to restore aesthetic prosthetics.



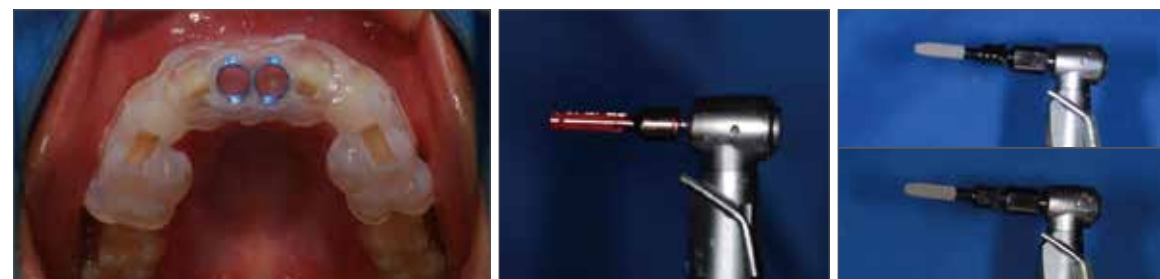Initial visitation oral scan image

Final restoration delivered panorama

Planning



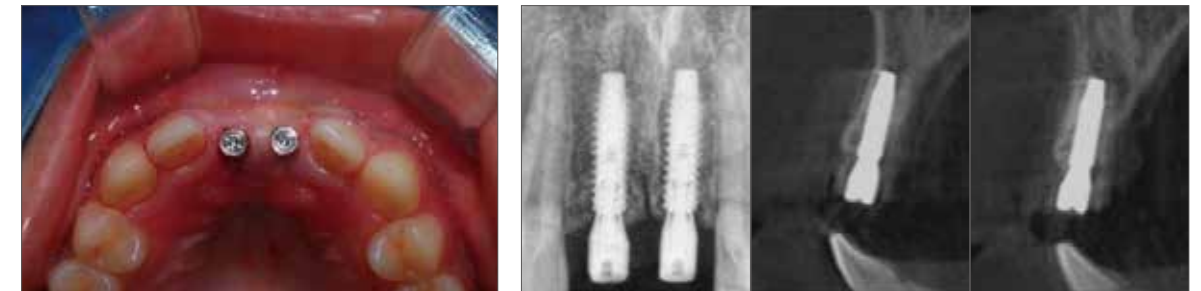DIONavi, Surgical Procedure



Surgical Guide fully seated

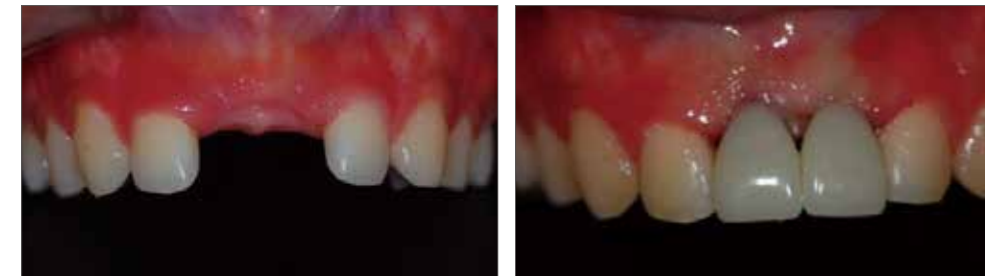Drilling

Fixture Placement

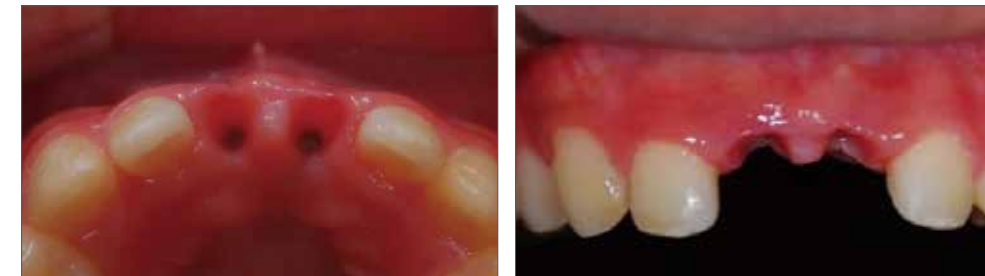

After connecting H-Scan Body, Temporary Crown is manufactured.

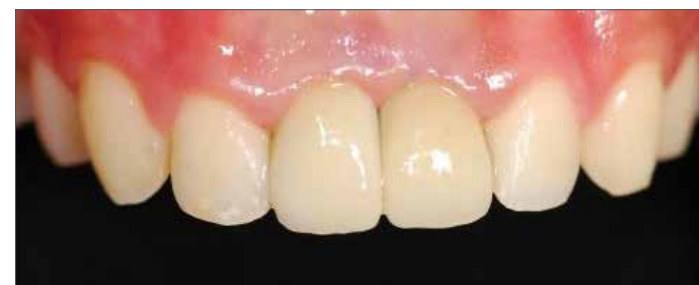After implant placement, panorama and CBCT images.



One week after implant placement, temporary prosthetics delivered.



Before mounting final prosthetics.



Oral image after mounting final prosthetics.

Prior to implant placement and using surgical simulation, outcomes can be predicted and thus the system has many advantages for use on maxillary anterior surgery that has many esthetic requirements.

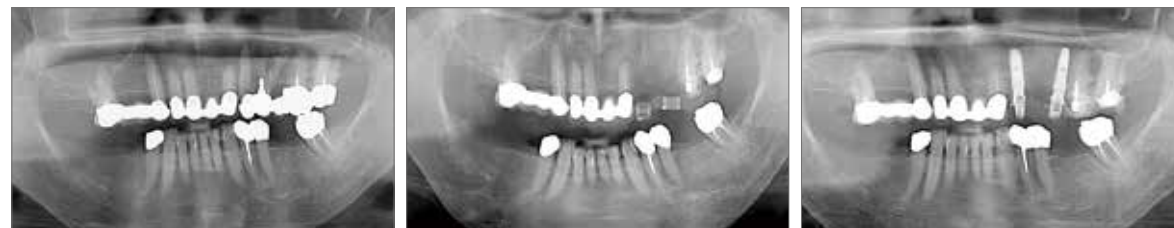As compared to solely relying on the surgeon's experience, a surgical procedure that can easily provide to anyone the ability to place implants at desired location and allows to make a prosthesis at optimal positions will provide better results.

Minimally Invasive Tooth Extraction Accompanied By Bone Graft and Immediate Implant Placement

Dr. Lee Hyang Yeon, Clinical Director Michigan Dental Clinic

Age 75 woman / Maxillary #23, 24, 26, 27 - 5 unit bridge state. Patient was aware of #23 and #24 needing extraction and removal of bridge but was worried about lack of bridge and teeth during the healing duration and delayed surgery.

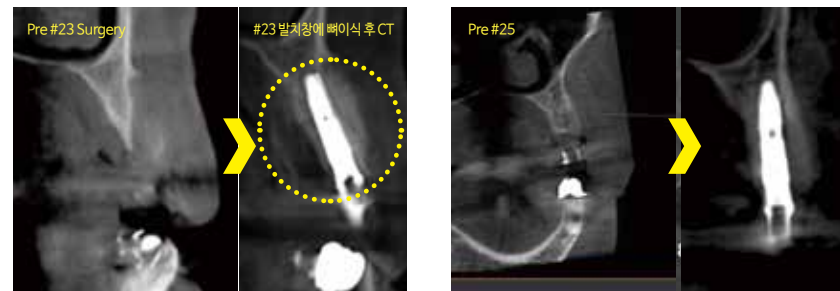
- After extraction of #23, immediate placement of UF(II) HSA Implant ϕ 4.0X13mm and bone graft
- #25 UF(II) HSA Implant ϕ 4.0X13mm.



Initial Examination Panorama

Post Extraction #23, 24 Panorama

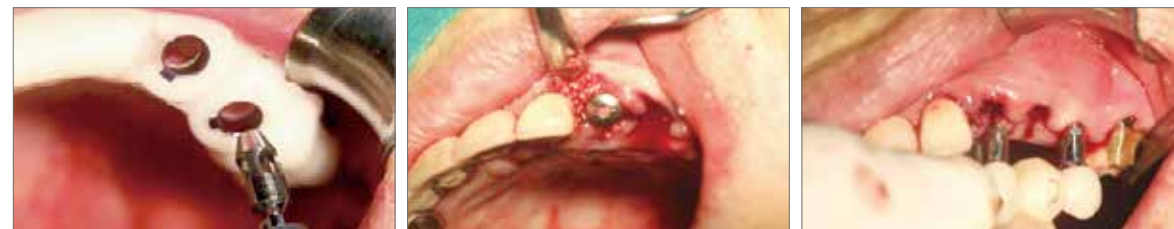Post DIONavi. Surgery Panorama



Pre and Post #23 Surgery CBCT Image
(Post bone graft at extraction socket implant placement)

Pre and Post #24 Surgery CBCT image

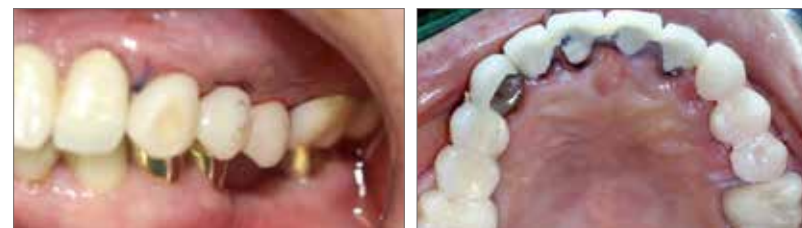DIONavi. Surgical Procedure



1. Surgical Guide fully seated and Removal of Soft Tissue with Tissue Punch

2. After Mounting Healing Abutment at #23, Extraction Socket Bone Graft

3. Customized Abutment & Abutment Jig setting



Abutment Jig setting

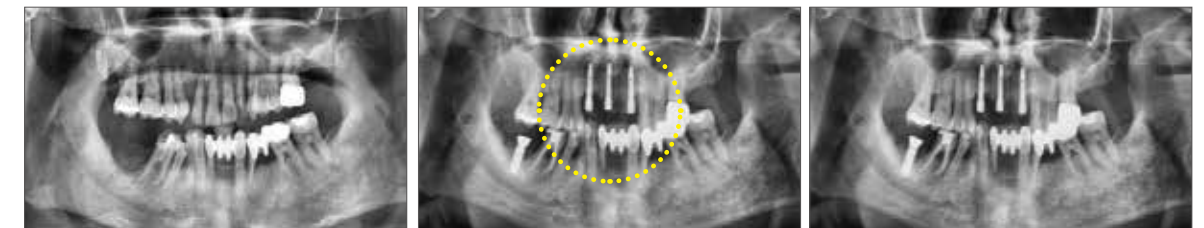
Abutment Jig One Week After Surgery

Anterior Region Tooth Extraction And Implant Placement With Consideration For Final Prosthetics

Dr. Lee Dong Ho, Clinical Director Allright Dental Clinic

Age 65 male / After tooth extraction, prevent sharp slippage during drilling through a Surgical Guide. In case of adjacent teeth used for guide anchorage has movement, use as a supplements Surgical Guide Fix Pin and Surgical Guide Fix used for edentulous cases.

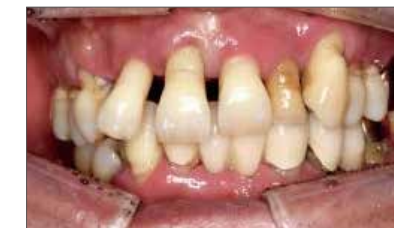- Surgical area #22, #13, #11 Complains of unsatisfactory aesthetics and movement of teeth in the anterior region due to usual periodontitis.
- Extraction of #12~#22; Implant Placement at #11, #13, #22 and Immediate Temporization



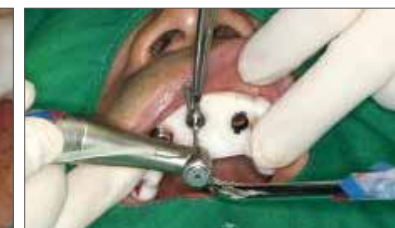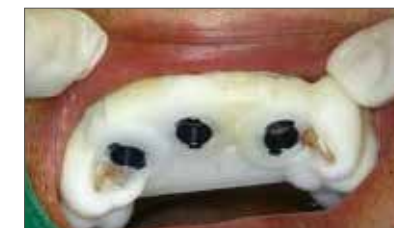Initial Examination Panorama

Post Surgery Panorama

Panorama After 3 Months

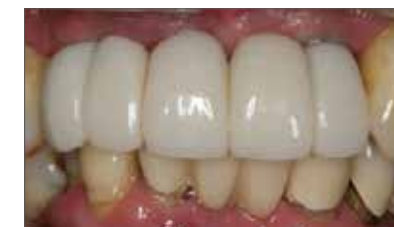
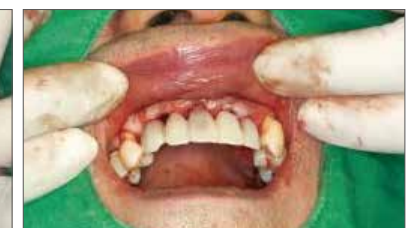
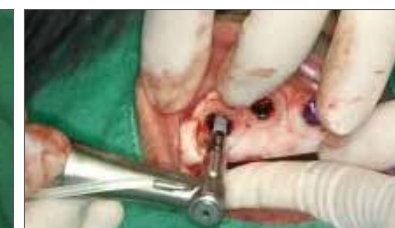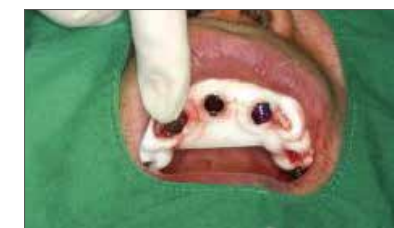Pre Surgical Condition: Movement of Teeth in Anterior Maxillary Region Due to Periodontitis.

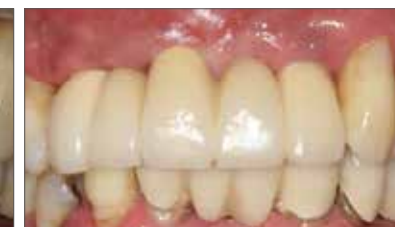

Surgical Procedures

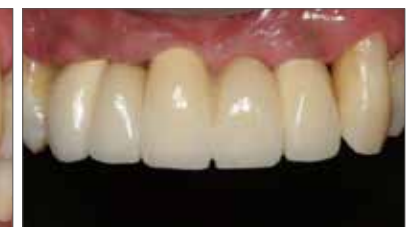Mobility of adjacent teeth, which may affect guide fixation, can be overcome by initial drilling on healed ridge #13 followed by guide fix pin to secure the surgical guide in position.



3 Months After Temporary Crown



6 Months After Oral Image

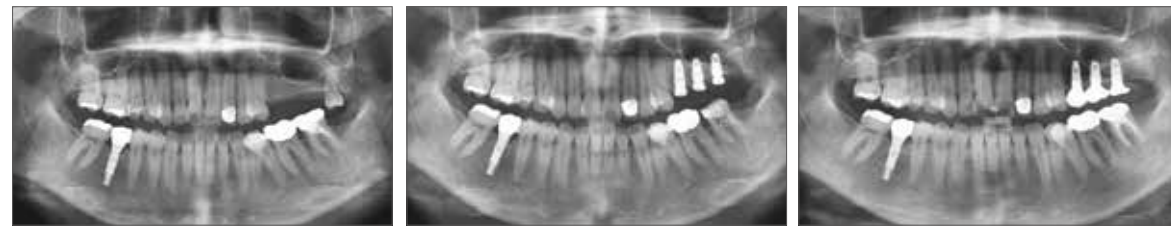

Sinus Lift Surgery Using CBCT Surgical Guide and Water Pressure

Choi Sung Ouk, Clinical Director Apple Tree Dental Clinic

Age 28 female / Loss of maxillary teeth #25-27 condition. Patient had insufficient amount of bone in the maxillary posterior. Used Digital Guided Surgery (DIONavi.) and Flapless Crestal Approach Sinus Elevation technique using water pressure to easily and quickly placed implants. Relative to Open Lateral Window Approach, this procedure was applied to reduce postoperative complications.

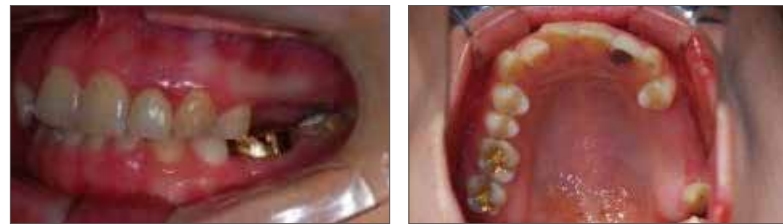- After fully seating the surgical guide, an implant was placed on #25
- Conducted #26, #27 flapless crestal approach sinus elevation and #28 was extracted for maintenance.



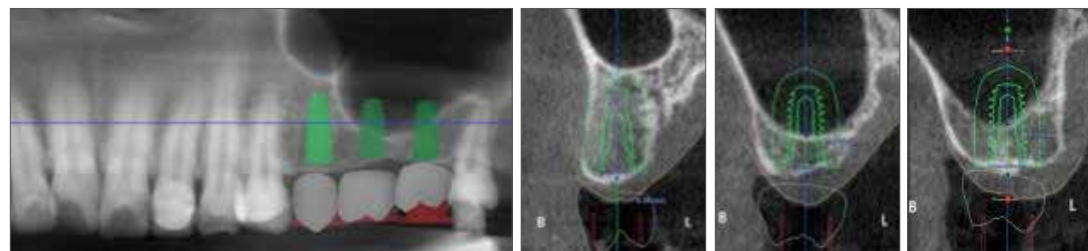
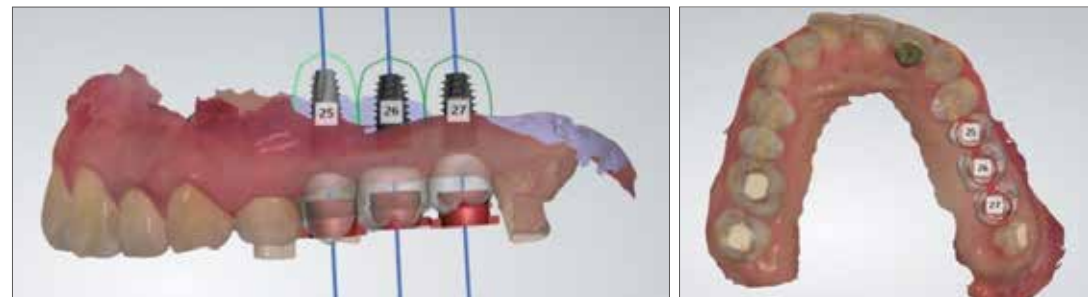
Initial Examination Panorama

Post Surgery Panorama

Post Final Prosthetics Mounting Panorama

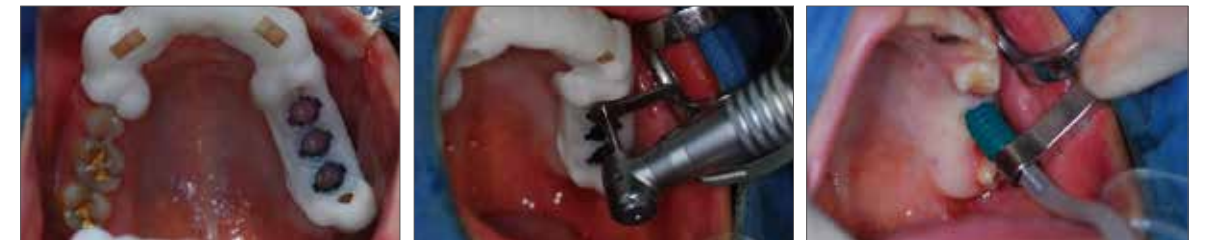

Initial Examination Oral Image



Planning

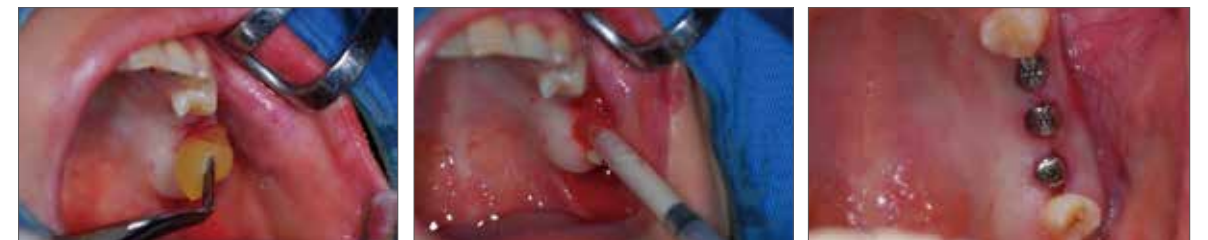DIONavi. Surgical Procedure



1. Surgical Guide seated

2. Drill Tube Connected and Initial Drilling

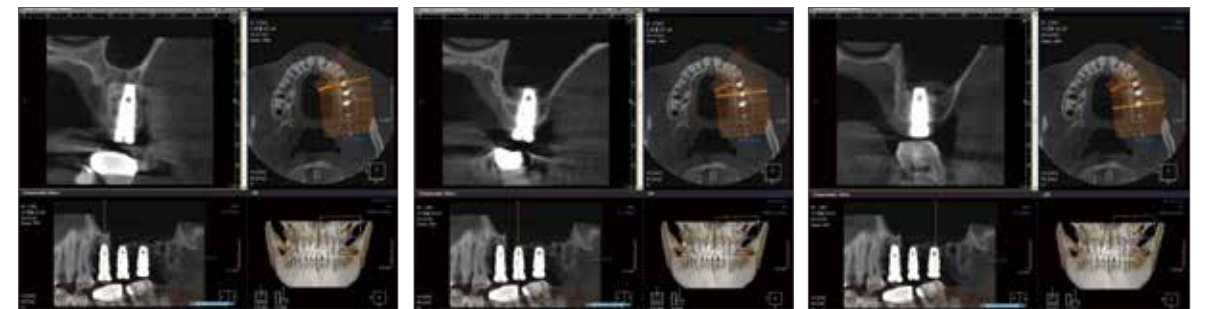
3. After Surgical Guide Removal, Water Pressure is Used For Sinus Lift.



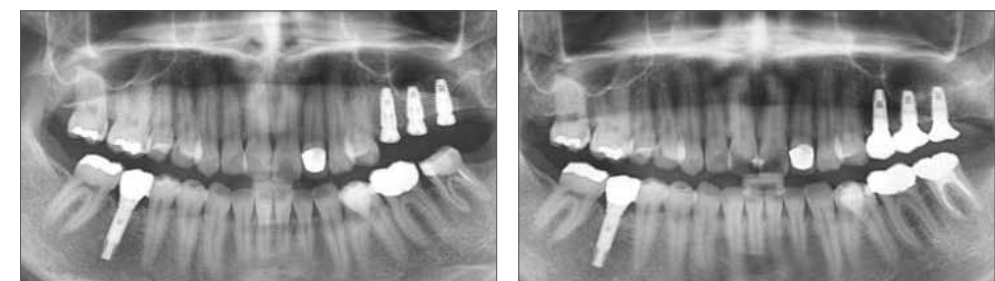4. PRF

5. Injection of Artificial Bone Material with Syringe

6. H Scanbody and Healing Abutment Connected

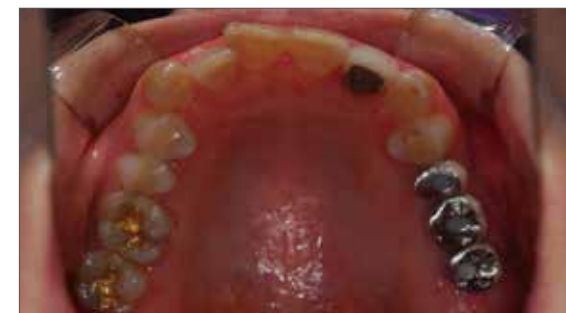

Post Surgical CT



Post Surgical Panorama

Panorama after mounting final prosthetics.



Post Final Prosthetics Mounting Oral Image

Crestal approach sinus lift done using DIONavi and water pressure offers the benefit of simple surgical procedure, and stability.

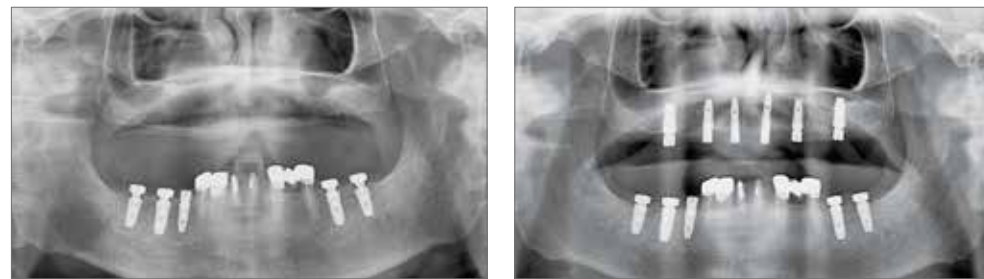
Maxillary Sinus Lift Accompanied by Maxillary Edentulous Implant Placement

Dr. Sohn Hyun Rak, Clinical Director Welcome Dental Clinic, Busan Station Branch

Age 66 Male / Existing Complete Maxillary Denture Condition

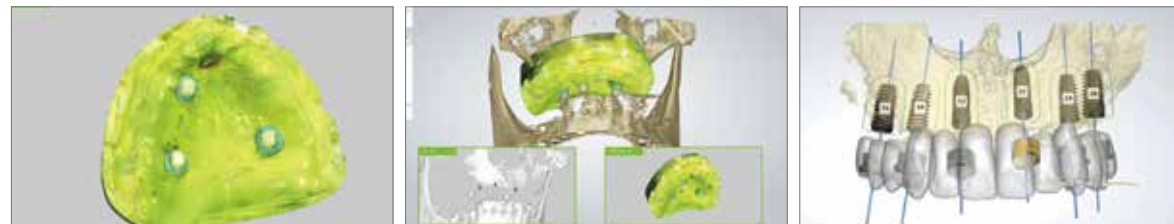
Dentures used for more than 10 years. Due to the resorption of the anterior labial bone, at the time of repair of prosthetics and related soft tissue management, there may rise aesthetic issues. Planned to place six implants and use Over Denture that does not cover the palate.

- # 16, 26 UF (II) ϕ 5.0 X 10.0 mm Fixture placement, #26 sinus elevation performed
- # 14, 24 UF (II) ϕ 4.5 X 10.0 mm Fixture / # 12, 22 UF (II) ϕ 3.8 X 11.5 mm Fixture



Initial Examination Panorama

Post DIONavi. Surgery Healing Abutment Connected

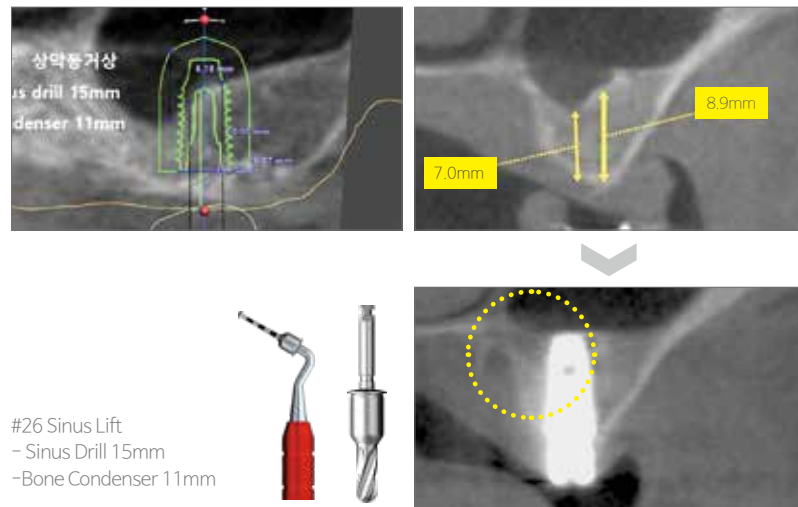
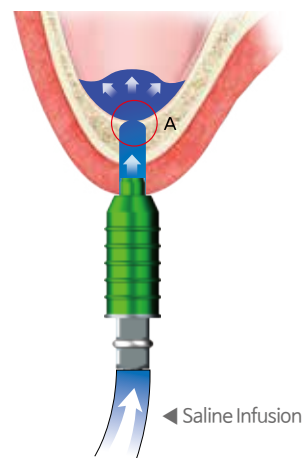


Template With Attached Markers and Stone Model Scanning

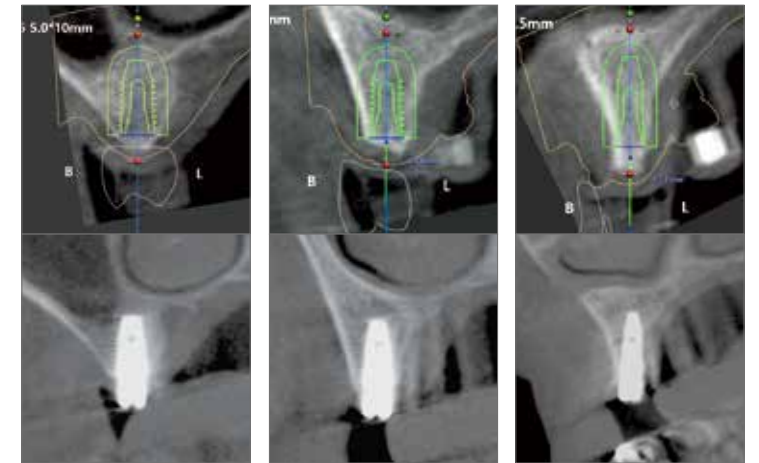
Merge Oral Scan Data and CBCT Data

Planning (Implant Studio-3Shape)

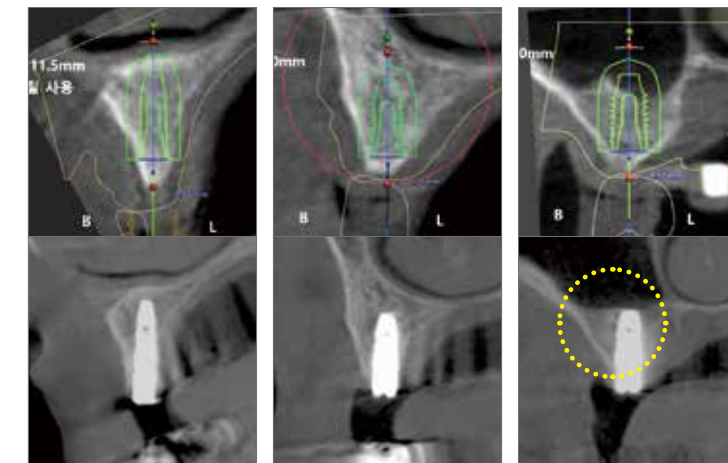
DIONavi. Sinus Surgery Procedure



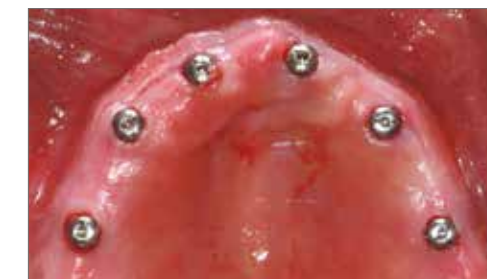#26 Sinus Lift
- Sinus Drill 15mm
- Bone Condenser 11mm



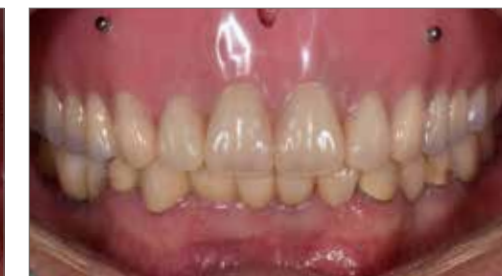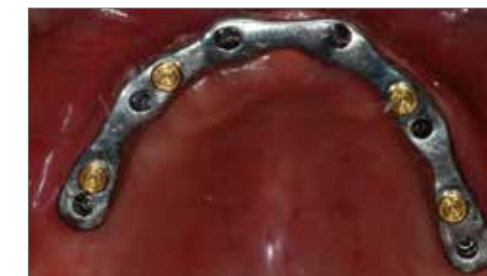#16 UF(II) HSA 5.0 X 10.0 mm #14 UF(II) HSA ϕ 4.5 X 10.0 mm #12 UF(II) HSA ϕ 3.8 X 11.5 mm



#22 UF(II) HSA ϕ 3.8 X 11.5 mm #24 UF(II) HSA ϕ 4.5 X 10.0 mm #26 UF(II) HSA ϕ 5.0 X 10.0 mm



Healing Abutment Connected



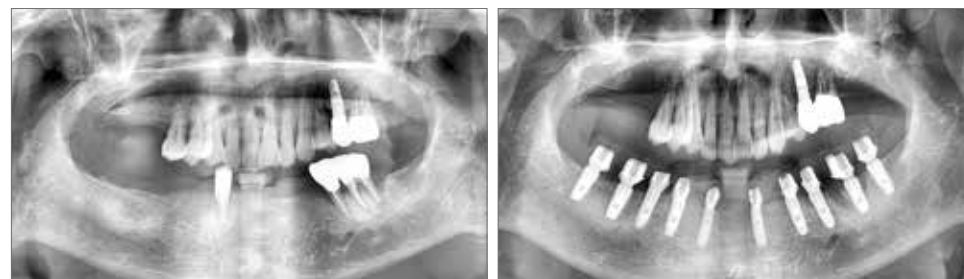
Final Prosthetics Mounted

Edentulous and Tooth Extraction With Consideration For Proper Occlusion of Final Prosthetics

Chung Dong Geun, Hospital Director SaeGaeRo Dental Hospital

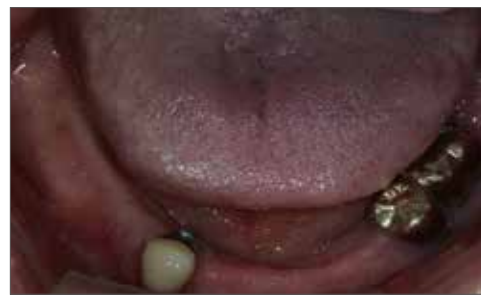Long-term use denture; #34 #35 has tooth mobility due to occurrence of periodontal disease and mandibular bone resorption.

- After extraction of #42, #34, & #35, placed implants at #32, #34, #35, #36, #37 / #42, #44, #45, #46, #47 → immediate temporization.

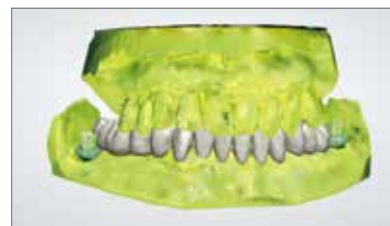

Pre Extraction #34, #35, #42

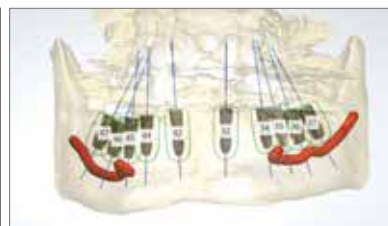Customized Abutment Connected



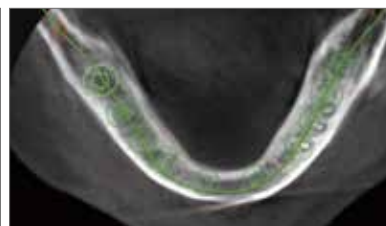Before Surgery



Occlusion Considered Crown Arrangement Design

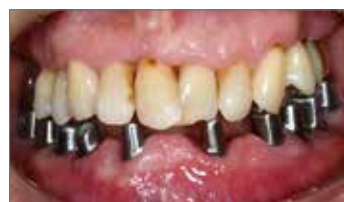
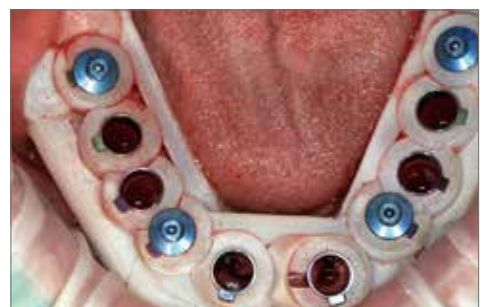
Implant Planning-1

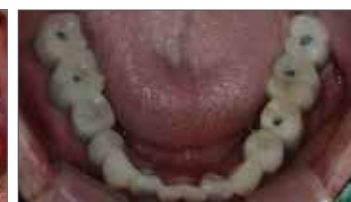

Implant Planning-2

DIONavi. Surgical Procedure

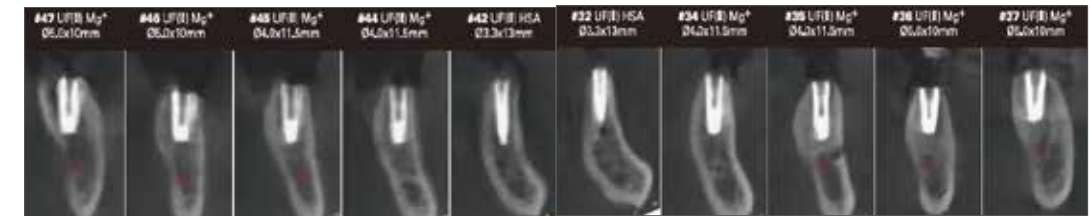


Custom Abutment Connected




Abutment Jig Attached on Day of Surgery

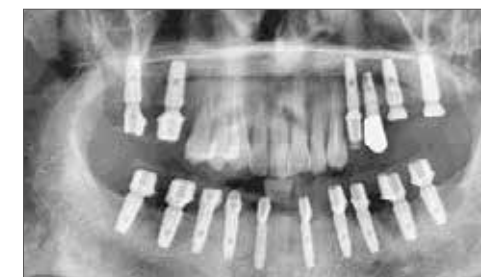Surgical Guide is fully seated to edentulous oral cavity and to improve stability, Guide Fix is connected after implant placement.



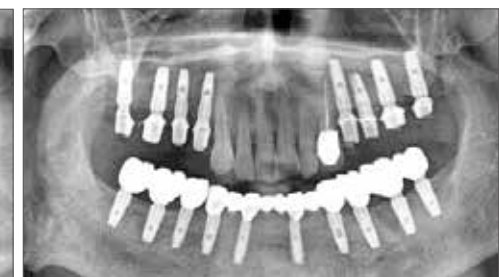
Post Surgery CBCT Images



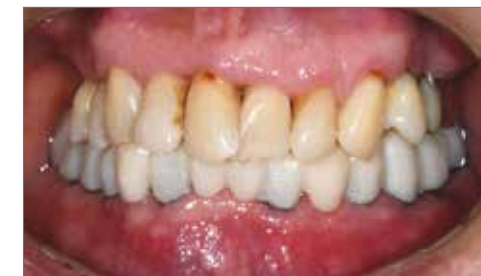8 Months Lapse Panorama



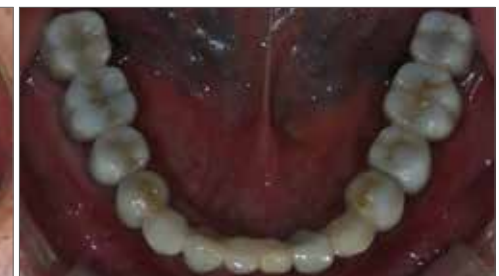Post Surgery 6 Months Panorama



Post Surgery 12 Months Panorama



Post Surgery Temporary Crown



Post Surgery 12 Months

Edentulous Case Guide Fix and Initial Drilling Accuracy Check

Fix Pin can be used to not only to fix the position of the Surgical Guide but also to check the accuracy of Initial Drilling. The initial drilling path may not be accurate if the bottom of fix pin and the guide do not make secure connection. By readjusting and correcting the initial drilling, accurate surgical outcome may be achieved.

As in this case, at the anterior (#31 or #41) and at posterior (#36, #46) positions, after conducting Initial Drilling, properly fasten Fix Pin ("tripodism") and then at the Premolar (#34, #44), molar (#36, #46) conduct implant placements first and then fasten Guide Fix to the Fixtures. Conducting these steps will produce more precise surgery.

Accuracy assessment of implant placement using a stereolithographic surgical guide made with digital scan

Source: Journal of Korean Academy of Prosthodontics, Vol. 53 (2015)

Seung-Mi Jeong1*, Jeong-Whan Fang1 Chan-Hyeon Hwang1 Se-Ha Kang1 Byung-Ho Choi2 Yiqin Fang2 Hyongtae Jeon3 Sunghun An3
Yonsei University, Wonju College of Medicine, 1 Department of Prosthodontics, 2 Department of Oral and Maxillofacial Surgery, 3 Busan Dio Implant Research Institute

Accuracy assessment of implant placement using a stereolithographic surgical guide made with digital scan

Seung-Mi Jeong1*, Jeong-Whan Fang1, Chan-Hyeon Hwang, Se-Ha Kang1, Byung-Ho Choi2, Yiqin Fang2, Hyongtae Jeon3, Sunghun An3
1Department of Prosthodontics, 2Department of Oral and Maxillofacial Surgery, Wonju College of Medicine, Yonsei University, Wonju, Republic of Korea
3Researcher, Dio research institute, Pusan, Republic of Korea

Purpose: The objective of this study was to evaluate the accuracy of a stereolithographic surgical guide that was made with information from intraoral digital impressions and cone beam CT (CBCT). **Materials and methods:** Six sets of resin maxilla and mandible models with missing teeth were used in this study. Intraoral digital impressions were made. The virtual models provided by these intraoral digital impressions and by the CBCT scan images of the resin models were used to create a surgical guide. Implant surgery was performed on the resin models using the surgical guide. After implant placement, the models were subjected to another CBCT scan to compare the planned and actual implant positions. Deviations in position, depth and axis between the planned and actual positions were measured for each implant. **Results:** The mean deviation of the insertion point and angulation were 0.28 mm and 0.26°, apex point were 0.11 mm and 0.14 mm respectively. The implants were situated at a mean of 0.44 mm coronal to the planned vertical position. **Conclusion:** This study demonstrates that stereolithographic surgical guides created without the use of impressions and stone models show promising accuracy in implant placement. (J Korean Acad Prosthodont 2015;53:)

Key words: CAD/CAM; Digital data; Digital impression; Digital implant; Guided surgery

Introduction

Digital computer-guided implant placement is a method of using digital scanned image and CBCT image to determine the position and angle of an implant, make a surgical guide that contains information about the position and angle of the implant, and perform implant placement using this guide. This method not only considers shape of bones but allows implant placement in a position appropriate for prosthetic treatment. Prosthesis to be placed on top of implant is designed before the surgery and made using CAD/CAM, so it can be attached immediately after implant placement. Also, there is an advantage of being able to perform flapless implant placement using a surgical guide.

The flapless surgery reduces bleeding during surgery and pain and discomfort after surgery. If an abutment is attached immediately, the wound can hardly be seen to improve esthetic quality of the prosthesis and shorten the healing period.^{1,2} Since the flapless surgery is a blind surgery that places implant through a small entrance formed on the gingiva without seeing the alveolar bone, it would be desirable to use a surgical guide with reliable accuracy. ³ Discrepancy of the surgical guide refers to the difference between position of implant planned out before the surgery and actual position of implant in the patient's mouth. According to literature review on discrepancy of the surgical guide, average position displacement

was 1.22mm at the top of implant and 1.51mm at the bottom of implant. Average angle error was 4.9°, and maximum error was 15.3°. Angle error of 15° is a value that can inflict critical damage on the adjacent anatomical structure. Surgical guides reported in the existing studies mostly involved the method of manually making a radiation guide and converting it into a surgical guide (manual method) or the method of manually making a radiation guide and turning it into a surgical guide by stereolithography.⁴⁻⁷ In this study, a surgical guide was designed using digital scanned image of the mouth and CBCT image without using impression material and plaster model, and the surgical guide was made using CAD/CAM. This surgical guide was used for accuracy assessment of dental implant.

Materials and Methods

1. Experimental Model

Six sets of partial edentulous maxilla and mandible models were used. The maxilla model was missing the central incisor, and the mandible model was missing the 1st and 2nd molar teeth on both sides (Fig. 1). The parts with missing teeth were covered with silicon gum of 2mm thickness, and the alveolar bone was manufactured using a wooden material of D1 bone quality.

2. Experimental Method

The model was regarded as the oral structure of the patient, and digital impression of the partial edentulous model was taken (Fig. 2, Fig. 3) using an oral scanner (TRIOSTM, 3Shape, Inc., Copenhagen, Denmark). The reference plate made for accuracy assessment of the surgical guide was used during CBCT imaging. The reference plate has 17 gutta-percha markers of 1mm diameter, and three markers were made to draw coordinate axes on X axis and Y axis.

The red lines in the figure are lines that indicate X axis and Y axis (Fig. 4). This plate is used to assess position of implant before and after the surgery. CBCT imaging was done after fixing the reference plate onto the occlusal surface of the model (Fig. 5).

The image file obtained from CBCT and the image file from digital impression were transmitted to an implant diagnostic software program (Implant StudioTM, 3Shape, Inc., Copenhagen, Denmark) and matched. Position of implant was diagnosed and the surgical guide was designed based on the matching image of the two images (Fig. 6, Fig. 7).

The image of the surgical guide was printed using a 3D printer (ProJet 3510 MP, 3D Systems, SC, USA) to make the actual surgical guide (Fig. 8).

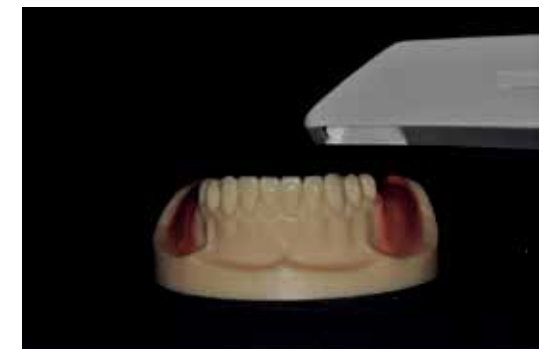


Fig. 2. Intraoral scanning of the resin model.

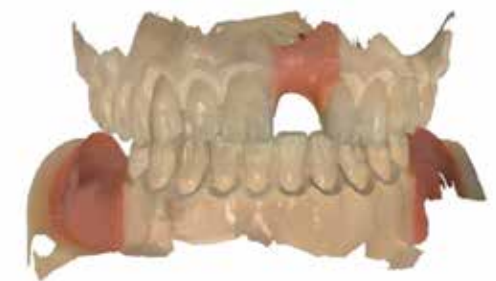

Fig. 3. Scanned model.

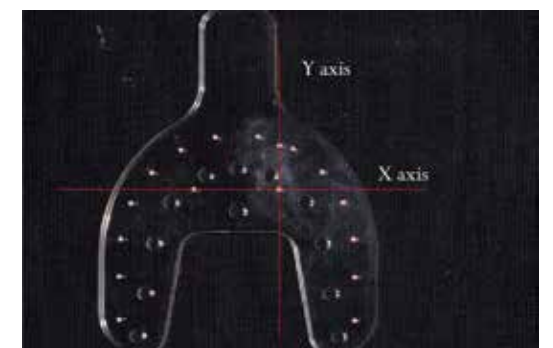


Fig. 4. Plastic plate for determination of a reference plane.

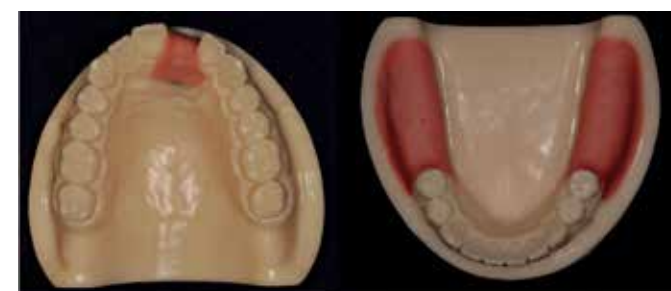

Fig. 1. Resin maxilla and mandible model with artificial silicone gums.

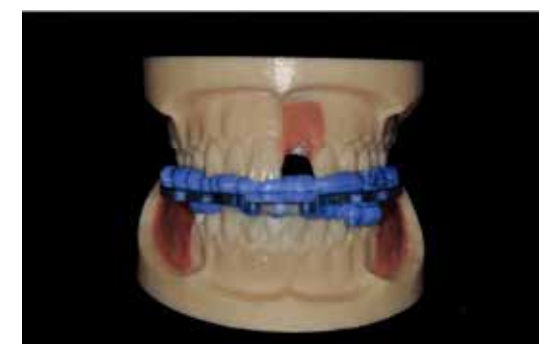

Fig. 5. Plastic plate attached to the resin model.

*Corresponding Author: Seung-Mi Jeong
Department of Prosthodontics, Wonju College of Medicine, Yonsei University, 20
Ilsan-ro, Wonju 220-701, Republic of Korea
+82 33 741 2114 : e-mail, smj3@yonsei.ac.kr
Article history: Received January 13, 2015 / Last Revision February 16, 2015 /
Accepted March 2, 2015

© 2015 The Korean Academy of Prosthodontic
This is an Open Access article distributed under the terms of the Creative
Commons Attribution Non-Commercial License (<http://creativecommons.org/licenses/by-nc/3.0>) which permits unrestricted non-commercial use, distribution,
and reproduction in any medium, provided the original work is properly cited.

※ This work was supported by a research grant from Yonsei University Wonju College of medicine (YUWCM-2008-25). pISSN 0301-2875 , eISSN 2005-3789

3. Implant Placement Using Surgical Guide

The surgical guide was used to perform flapless implant on the six sets of partial edentulous maxilla and mandible models. After stable attachment of the surgical guide to the model, soft tissue punch of 3mm diameter was inserted into the sleeve of the surgical guide in position of implant and rotated to remove the silicon gum.

Drilling was done to 10mm depth using DIO NAVI Surgical Kit (Busan, Korea). The first drill used was a $\varnothing 2.0$ mm drill.

A drill tube for the $\varnothing 2.0$ mm drill was inserted into the sleeve of the surgical guide, and the drill was inserted into the hole at the center of the tube for drilling. The drill tube had guide height of 9 mm (Fig. 9), space of 0.01 mm with the sleeve, and space of 0.02 mm with the drill (Fig. 10). Following the path created by the first drill, $\varnothing 2.8$ mm, $\varnothing 3.3$ mm, $\varnothing 3.8$ mm and $\varnothing 4.3$ mm drills were used in the given order.

All drills have a stop at the top, and drilling was performed at low speed (50 rpm) until this step reached the top of the surgical guide. After drilling, five implants (UF II, DIO Implant, Busan, Korea) were placed (Fig. 11) at the same depth using the same method on each of the six maxilla and mandible models, on both sides of maxillary incisor and mandible molar.

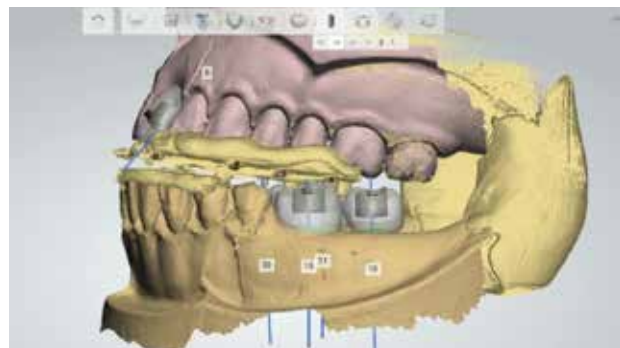


Fig. 6. The merged image of the CBCT scan and the intraoral scan.

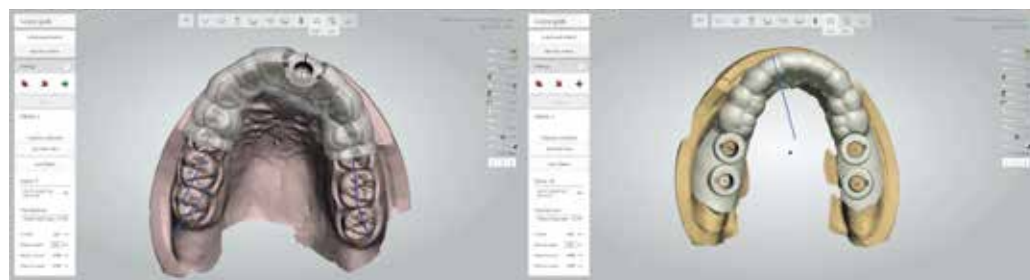

Fig. 7. Virtual surgical guides for the maxilla (A) and mandible (B).

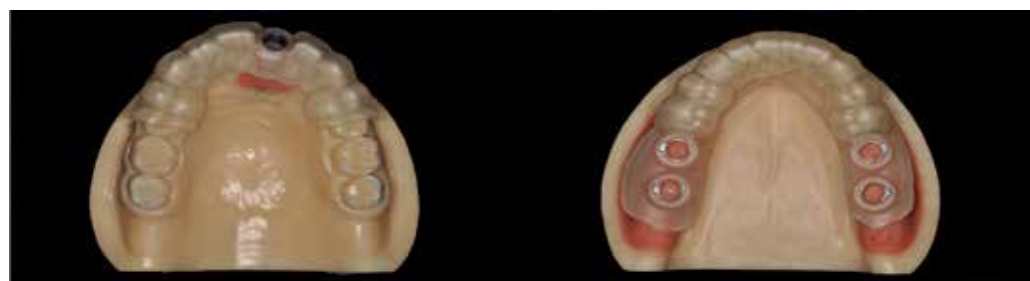


Fig. 8. Surgical guides for the maxilla (A) and mandible (B).

4. Accuracy Assessment of Surgical Guide

After implant placement, 2nd CBCT imaging (PointNix, Seoul, Korea) was done in the same way as the first with the reference plate fixed onto the occlusal surface of the model. CBCT images before and after placement were matched using the reference plate, SimPlant software program (Materialise, Leuven, Belgium) was used to find the coordinate values for position of implant in the following way.

The line that connects the center of two gutta-percha markers placed horizontally on the plate was set as the X axis, the line that connects the center of two gutta-percha markers placed vertically was set as the Y axis, the intersection point of X and Y axes was set as the O point, and the axis perpendicular to the XOY plane was set as the Z axis (Fig. 12).

The topmost point on the central axis of implant was defined as P (insertion point), and the bottommost point as P' (apex point). The coordinate values of P on the XOY plane, P (x, y) and P' (x', y'), were found. Angles $X\theta$ and $Y\theta$ at which the XOY plane meets the central axis of implant were found (Fig. 13).

Vertical discrepancy was calculated in the Z axis direction of P and P'. Discrepancies of implant distance and angle were calculated in the direction of X axis and Y axis through this process, and discrepancy of vertical depth was calculated in the direction of Z axis (Fig. 14, Fig. 15).

5. Statistical Method

SPSS Ver. 19.0 (SPSS Inc, Chicago, IL, USA) program was used to perform t-test for comparison of horizontal discrepancy and vertical discrepancy. Also, statistical significance level of $P < 0.05$ was used to compare discrepancies of one maxillary implant and four mandibular implants



Fig. 9. Guide tube of 9 mm in length.

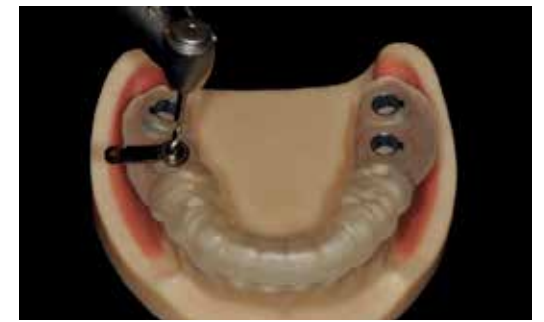

Fig. 10. Drilling through the guide tube with a 2 mm drill.

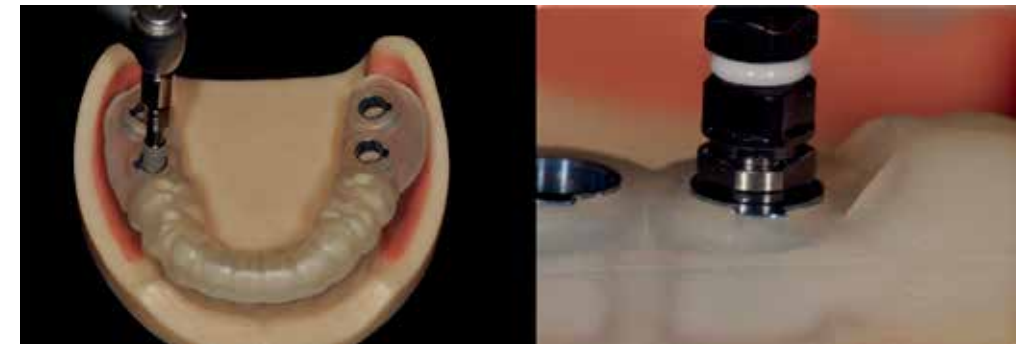

Fig. 11. Surgical guides: Implant placement using the guide (A) and implant connector position at buccal view (B).

Results

All surgical guides made were very stable when attached to the models (Fig. 16). Table 1 presents discrepancies of distance, angle and vertical height of implants in the direction of X axis, Y axis and Z axis.

Average distance discrepancy (ΔX , ΔY) at the top point of implant was 0.27 ± 0.11 mm in the direction of X axis and 0.29 ± 0.13 mm in the direction of Y axis. Average distance discrepancy ($\Delta X'$, $\Delta Y'$) at the bottom point was 0.11 ± 0.10 mm in the direction of X axis and 0.14 ± 0.10 mm in the direction of Y axis. Average angle discrepancy ($\Delta X\theta$, $\Delta Y\theta$) was $0.26 \pm 0.10^\circ$ in the direction of X axis and $0.26 \pm 0.11^\circ$ in the direction of Y axis.

Average vertical discrepancy (ΔZ) was 0.44 ± 0.17 mm, and all implants were placed higher than planned vertical height. Discrepancy of vertical height was greater than horizontal discrepancy, and this difference was statistically significant. There was no statistically significant difference between discrepancy of single implant and discrepancy of multiple implants.

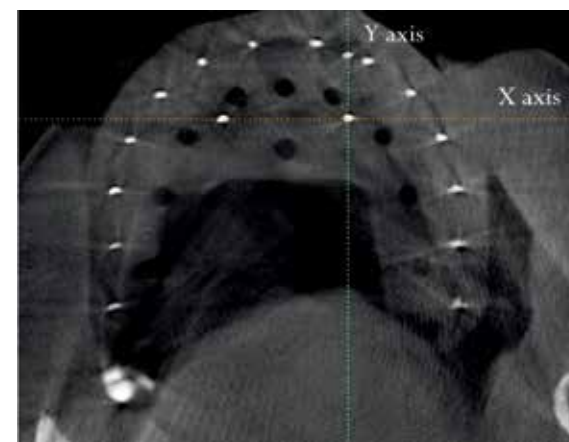


Fig. 12. The X- and Y-axis on the CBCT image.

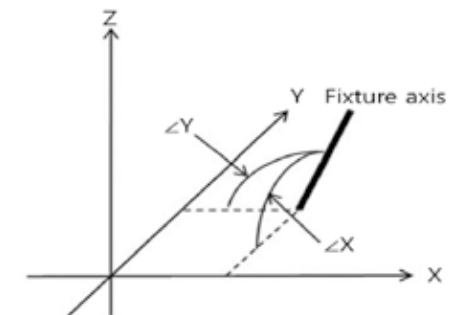


Fig. 13. These illustrations show the procedure used to determine the position and angle of the virtual implant. The insertion point P (X, Y) and apex point P' (X', Y') is determined by the crossing point between the axis of the virtual implant and the XOY-plane. $\angle X$ ($X\theta$) and $\angle Y$ ($Y\theta$) are defined as the angles from the X- and Y-axes, respectively.

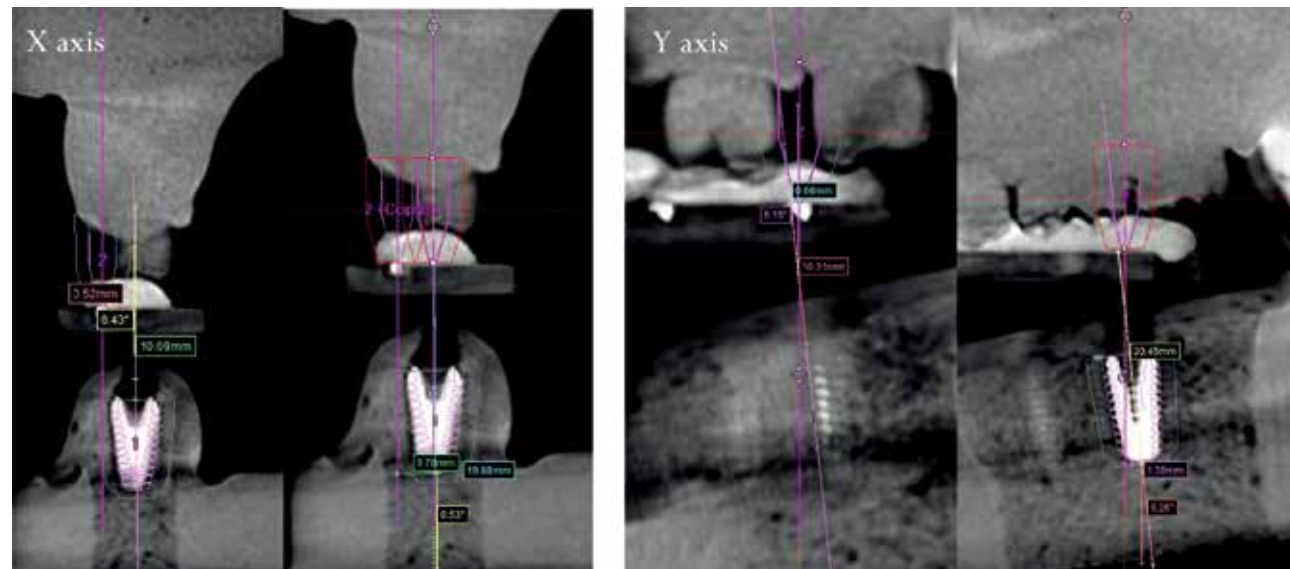


Fig. 14. Position and angulation of the implant on the CBCT image.

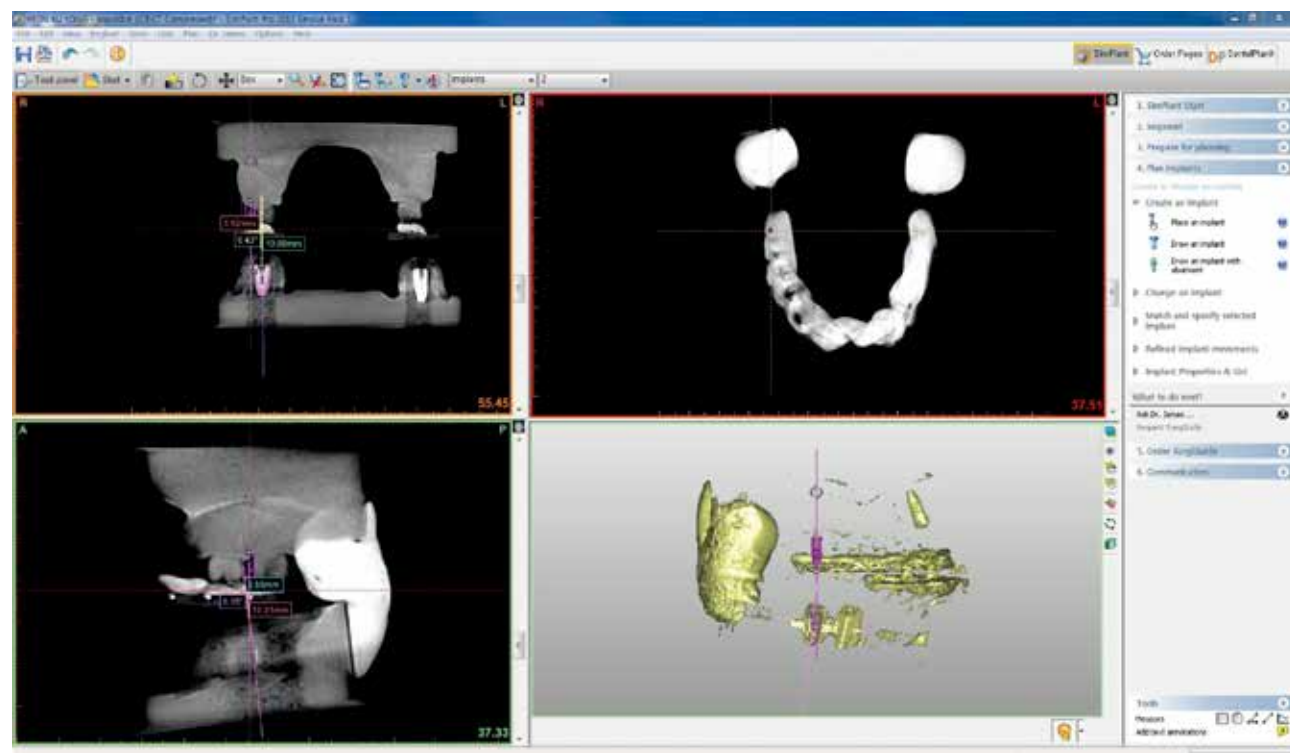


Fig. 15. Position and angulation of the implant on the Simplant software.

Discussions

In this study, digital impression taking was used to scan and obtain digital image of teeth and mucous membrane using an oral scanner. This removes the need for the conventional impression taking process and plaster model. Also, there is no discomfort of having to send plaster model or impression material via postal mail. Making the surgical guide using digital impression has an advantage of shortening time of manufacture, as digital data are sent through the internet. In addition, the manufacturer and operator can easily share real-time information about the patient.¹⁰

Various methods were used and continuously developed to make surgical guides. These methods are as follows. The first method is to manually make a radiation guide and convert it into a surgical guide (manual method).^{8,9} This method makes a radiation guide based on a resin template with a reference marker in a plaster model obtained by taking oral impression of a patient, takes a CBCT image after attaching the radiation guide to the inside of the mouth, obtains position information of implant based on the marker on the CBCT image, and fixes the sleeve onto position of the radiation guide to convert it into a surgical guide.

The second method is to manually make a radiation guide and then make a surgical guide by stereolithography (stereolithography method).⁴⁻⁷ This method makes a radiation guide based on a resin template with a reference marker in the plaster model obtained by taking oral impression of a patient, takes a CBCT image after attaching the radiation guide to the inside of the mouth, and takes an image of the radiation guide once again.

These two CBCT images are overlapped on the reference marker to design a surgical guide. A 3D printer (stereolithography) is used to make the actual surgical guide. The third method is a method of making a surgical guide using scanned image of plaster model, CBCT image and CAD/CAM (partial digital method).

This method uses an image created by overlapping impression image of a plaster model and CBCT image to design a surgical guide and makes the surgical guide using a 3D printer.

The fourth method is a method of making a surgical guide using oral scanning image, CBCT image and CAD/CAM (full digital method).¹¹⁻¹³ This method uses an image created by overlapping two digital data, oral scanning image and CBCT image, without a plaster model to design a surgical guide and makes the surgical guide using a 3D printer. Most of existing studies reviewed used the manual method or stereolithography method to make surgical guides.⁴⁻⁹ According to data on discrepancies of surgical guides made using the methods presented, average position displacement was 1.22 mm at the top of implant and average angle discrepancy was 4.9°.⁴⁻⁹

In this study, the full digital method was used to make the surgical guides without using impression material and plaster model. Average discrepancy of the surgical guides was 0.28 mm and 0.11 mm at the top and bottom of implant, and average angle discrepancy was 0.26°. The results showed much higher accuracy compared to surgical guides reported in the existing studies. The primary causes of high accuracy are reduction of discrepancy during manufacture of the surgical guides and reduction of surgical discrepancy related to implant placement. When the surgical guides are made using the full digital method without using impression material and plaster model, discrepancy caused by deformation from hardening of impression material and plaster is removed, and there is no discrepancy from the process of making radiation guide.^{7,14-19}

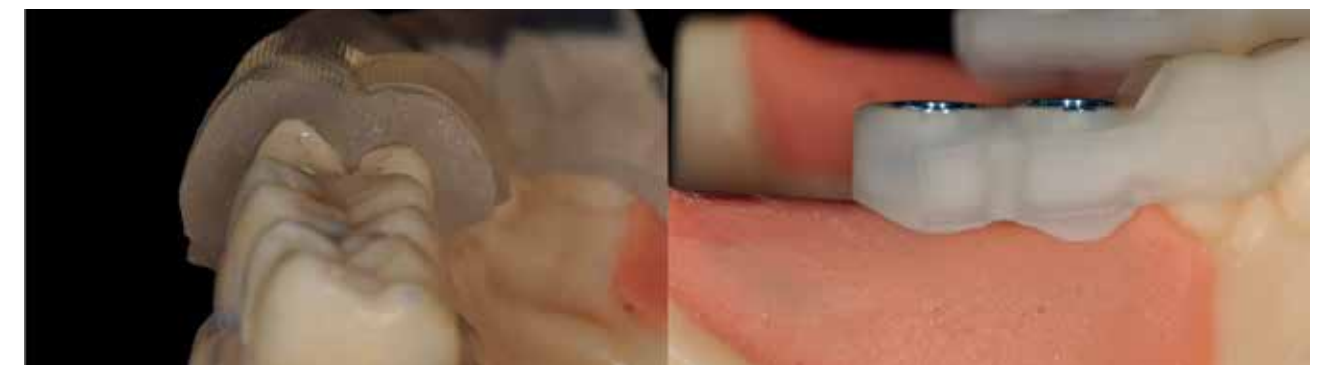

Fig. 16. Surgical guides on the resin maxilla (A) and mandible models (B).

Table 1. Determine the position and angle of the virtual implant at X, Y, Z-axes. The insertion point P (X, Y) and apex point P' (X', Y') are determined by the crossing point between the axis of the virtual implant and the XOY-plane. $\angle X$ ($X\theta$) and $\angle Y$ ($Y\theta$) are defined as the angles from the X- and Y-axes, X ($X\theta$) and $\angle Y$ ($Y\theta$) are defined as the angles from the X- and Y-axes. ΔZ is defined as vertical discrepancy

Discrepancy	ΔX (mm)	$\Delta X'$ (mm)	ΔY (mm)	$\Delta Y'$ (mm)	$\angle X\theta(^{\circ})$	$\angle Y\theta(^{\circ})$	ΔZ (mm)
Mean	0.27	0.11	0.29	0.14	0.26	0.26	0.44
SD	0.11	0.10	0.13	0.08	0.10	0.11	0.17

Average vertical discrepancy was 0.44 ± 0.17 mm, and all implants were placed above planned vertical height. This vertical discrepancy probably resulted from the process of making the surgical guides using the full digital method. In other words, discrepancies that occur during the processes of oral scanning, image matching and making actual surgical guide were combined to result in vertical discrepancy during the surgery. This vertical discrepancy leads to plus vertical discrepancy, which means that implant is not placed as deep as planned out. Therefore, when performing implant placement using a surgical guide made by the full digital method, such vertical discrepancy needs to be corrected during or immediately after implant placement.

Conclusions

The results of this study showed that implant can be placed accurately according to position and angle planned out by performing implant placement with a surgical guide made using digital oral scanning without a plaster model.

ORCID

References

1. Jeong SM, Choi BH, Xuan F, Kim HR. Flapless implant surgery using a mini-incision. *Clin Implant Dent Relat Res* 2012;14:74-9.
2. Sclar AG. Guidelines for flapless surgery. *J Oral Maxillofac Surg* 2007;65:20-32.
3. Terzioğlu H, Akkaya M, Ozan O. The use of a computerized tomography-based software program with a flapless surgical technique in implant dentistry: a case report. *Int J Oral Maxillofac Implants* 2009;24:137-42.
4. DiGiacomo GA, Cury PR, de Araujo NS, Sendyk WR, Sendyk CL. Clinical application of stereolithographic surgical guides for implant placement: preliminary results. *J Periodontol* 2005;76: 503-7.
5. Rupp J, Popovic A, Strauss M, Spüntrup E, Steiner A, Stoll C. Evaluation of the accuracy of three different computer-aided surgery systems in dental implantology: optical tracking vs. stereolithographic splint systems. *Clin Oral Implants Res* 2008;19:709-16.
6. Van Assche N, van Steenberghe D, Guerrero ME, Hirsch E, Schutyser F, Quirynen M, Jacobs R. Accuracy of implant placement based on pre-surgical planning of three-dimensional cone-beam images: a pilot study. *J Clin Periodontol* 2007;34:816-21.
7. van Steenberghe D, Naert I, Andersson M, Brajnovic I, Van Cleynenbreugel J, Suetens P. A custom template and definitive prosthesis allowing immediate implant loading in the maxilla: a clinical report. *Int J Oral Maxillofac Implants* 2002;17:663-70.
8. Kalt G, Gehrke P. Transfer precision of three-dimensional implant planning with CT assisted offline navigation. *Int J Comput Dent* 2008;11:213-25.
9. Nickenig HJ, Eitner S. Reliability of implant placement after virtual planning of implant positions using cone beam CT data and surgical (guide) templates. *J Craniomaxillofac Surg* 2007; 35:207-11.
10. Hajeer MY, Millett DT, Ayoub AF, Siebert JP. Applications of 3D imaging in orthodontics: part II. *J Orthod* 2004;31:154-62.
11. Flügge TV, Nelson K, Schmelzeisen R, Metzger MC. Three-dimensional plotting and printing of an implant drilling guide: simplifying guided implant surgery. *J Oral Maxillofac Surg* 2013;71:1340-6.
12. Lee CY, Ganz SD, Wong N, Suzuki JB. Use of cone beam computed tomography and a laser intraoral scanner in virtual dental implant surgery: part 1. *Implant Dent* 2012;21:265-71.
13. Stapleton BM, Lin WS, Ntounis A, Harris BT, Morton D. Application of digital diagnostic impression, virtual planning, and computer-guided implant surgery for a CAD/CAM-fabricated, implant-supported fixed dental prosthesis: a clinical report. *J Prosthet Dent* 2014;112:402-8.
14. Torassian G, Kau CH, English JD, Powers J, Bussa HI, Marie Salas-Lopez A, Corbett JA. Digital models vs plaster models using alginate and alginate substitute materials. *Angle Orthod* 2010;80:474-81.
15. Akyalcin S, Cozad BE, English JD, Colville CD, Laman S. Diagnostic accuracy of impression-free digital models. *Am J Orthod Dentofacial Orthop* 2013;144:916-22.
16. Horwitz J, Zuabi O, Machtei E. Radiographic changes around immediately restored dental implants in periodontally susceptible patients: 1-year results. *Int J Oral Maxillofac Implants* 2008;23: 531-8.
17. Jung RE, Schneider D, Ganeles J, Wismeijer D, Zwahlen M, Hammerle CH, Tahmaseb A. Computer technology applications in surgical implant dentistry: a systematic review. *Int J Oral Maxillofac Implants* 2009;24:92-109.

Guided immediate loading implant surgery planned with DIONavi.

Jaemin Lee

- International member of American Academy of Periodontology
- Korean Academy of Esthetic Dentistry
- Official member of Korean Academy of Digitalized Dentistry
- Official member of Korean Academy of Esthetic Orthodontics
- Clinical researcher of DIO Digital Implant

Prologue

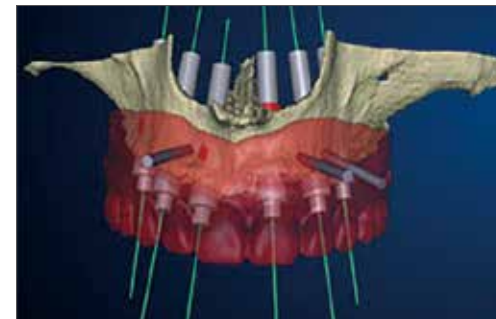
How can we deal with the immediate loading implant cases easier and more accurate than before?

This question has always been on my mind for the past few years. Even after I became confident on applying immediate loading protocol to fully or partially edentulous patients, still it was very hard to place implants with properly made temporary prosthesis at the same time. After a surgery has ended, there always were stitches, blood and damaged soft tissue in the mouth. These things made it hard to make provisional prosthesis right after the surgery has ended. This led me to draw a conclusion that immediate loading case should go with planned surgery and pre-fabricated provisional prosthesis.

So I started to search for a proper guide surgery system which would offer me an accurate surgical guide and prefabricated immediate prosthesis at the same time. However the guide surgery systems on the market at that time, did not satisfy my needs completely. Their work-flow was very hard to follow, from diagnosis to guide fabrication. Moreover, it was much harder to make immediate prosthesis with their system. Even though the guide was made with CAD system, still temporary prosthesis should be made upon the cast model by help of the guide.



[Figure 1] A captured image from Implant Studio – Implant Studio can both plan surgery and design prosthesis in a fully digitalized way



[Figure 2] Designing and fabricating surgical guide with Nobel Guide – Nobel Guide can plan surgery digitally, but designing implant prosthesis should be done manually over the stone cast.

It was early 2014 that I first started dental CAD/CAM to make dental prosthesis in my office. At that time, I purchased Trios 2 and a wet mill machine to produce one-day restorations. One day, my partner from DIO Implant, one of the major 3Shape's resellers, told me there was a nice surgical guide system from 3Shape. My eyes opened wide when I first heard of it. Because it was exactly what I was looking for. With DIONavi. I could plan the whole surgery and also design the temporary prosthesis. There was no reason to hesitate trying this and I started guide surgeries supported by DIONavi.

What is Implant Studio?

Implant Studio is a CAD program which is developed by 3Shape, one of the leading companies in dental CAD/CAM market. What makes Implant Studio more special than other systems is that it can both plan implant surgery and design implant prosthesis at the same time.



[Figure 3] Trios and D2000, 3Shape's most advanced oral scan solutions

This could be achieved by 3Shape's highly advanced dental CAD technology and their state of the art intraoral scanner Trios and model scanner D-series. 3Shape's scanners do not allow more than

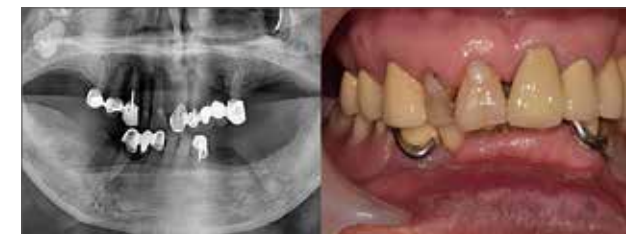0.05mm of error and the integration procedure between CBCT data and oral scan data is very accurate. Through this integrated data, DIONavi. can plan surgeries in a fully digitalized way, with great precision that is ever seen before

How DIONavi Works?

It would be better showing a case done with DIONavi. than describing the work flow in a narrative way. Here, one of my case will be followed.

1. PATIENT HISTORY

This patient was wearing a removable partial denture on lower jaw when he visited my office for the first time. He said 3unit bridged crowns on lower right side had problems. From X-ray view, I could find periapical lesions around the root tip of lower right canine and lower left incisor and there were also secondary caries around the margin of bridged crowns.

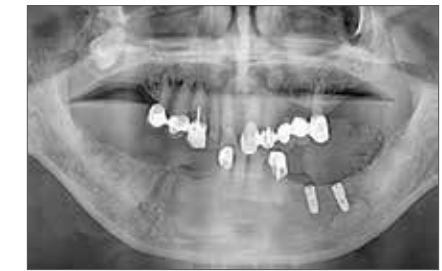

[Figure 4] Panoramic X-ray and a Photo taken on the first visit

He already knew that those teeth needed to be extracted at that time. But there was one thing he eagerly wanted, he wanted to maintain his RPD in use, until the implants on both side of lower jaw are finished. So we agreed to extract #41, 43 and place implants on left side first. Until the implant treatment is finished, he would be able to use his RPD which was fixed to be used further. After the implant crowns on left side were set then the implants on left side were supposed to be placed.

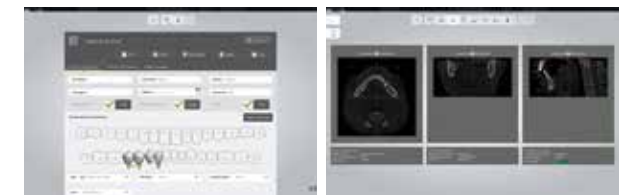On the first treatment day, as planned, #41 and 43 were extracted and two implants were placed on the left side of lower jaw. And his RPD was repaired to be used as a temporary denture.

However, after 5weeks, the denture was completely separated into two parts. The patient was very disappointed about not being able to chew anything with his remained teeth. He insisted on repairing the RPD but it was impossible due to the sublingual bar was completely broken. As he wanted temporary prosthesis on both sides of his lower jaw, there wasn't any choice but the immediate loading implants on the right side. I suggested an immediate loading guided implant surgery on the right side and finishing the prosthetic procedures on the left side earlier than the plan. He agreed, and I could start preparing for the surgical guide.



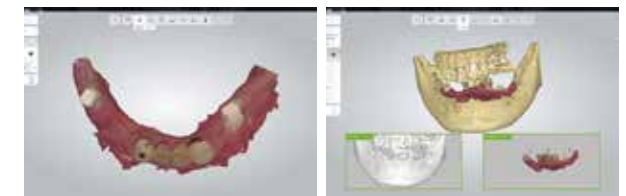
[Figure 5] #41, #43 were extracted on the first treatment day. Implants were placed on #34, #35 position.

2. PLANNING SURGERY WITH IMPLANT STUDIO



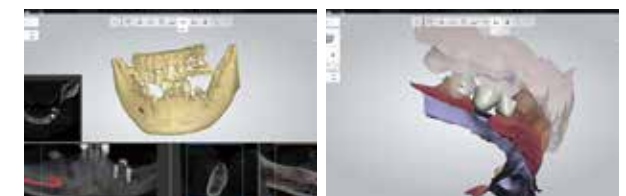
[Figure 6] Order page

[Figure 7] Cropping CT image




[Figure 8] Oral Scan Image

[Figure 9] Scan Alignment



[Figure 10] Nerve Definition

[Figure 11] Provisional Crown Design



[Figure 12] Implant Planning

1) Order page :

It all starts with this page, here you should load scan files and CT scan files in dicom format. After that, you can input the details about the surgery.

2) Cropping CT image :

You can cut out the unnecessary area of CT image here. This can reduce the file size so that the program can be operated more stable.

3) Oral Scan Image :

Here, markers are attached to get better integration. With those radiopaque material, you can get additional points to integrate a CT image and an oral scan image.

4) Scan Alignment :

This process is the most important one among all the procedures while operating Implant Studio because if the integration fails then the whole surgical plan can go failure also. As you can see from the picture, there are 3 points you should pick. Normally natural teeth are the best choice for the integration, because they are not blurred in CT image and easily seen in the oral scan image. In this picture, PFM crowns were blurred in CT image and due to the multiple loss of teeth, both end sides of lower jaw do not have points to be used as integration points. In this case, the markers can act like natural teeth so that you may get the integration easier and more accurate.

5) Nerve Definition :

To keep the inferior alveolar nerve unharmed, drawing nerve line must be done. It is easy and intuitive, just pick some points from the start to end of the nerve the line is drawn automatically.

6) Provisional Crown Design :

Just drag and tilt the preformed crowns as you have in mind.

7) Implant Planning :

Now it is time to place the fixtures. DIONavi. always plans a surgery after the virtual prosthesis is placed upon the gingiva. This means the prosthetic result is fully anticipated before surgery. You can avoid bad placement of fixtures by watching the positional relation between fixtures and projected crowns. Even if there might be some anatomic features that prohibit the right placement of implants, still you can handle it before making final prosthesis. Real prosthesis leading surgery is now possible with Implant Studio.

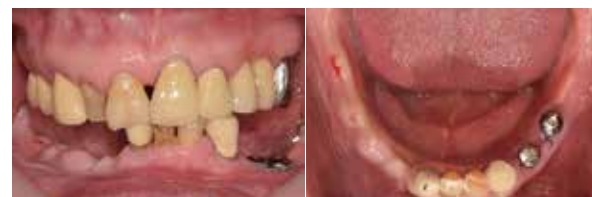3. SURGERY

1) Photos taken before the surgery :

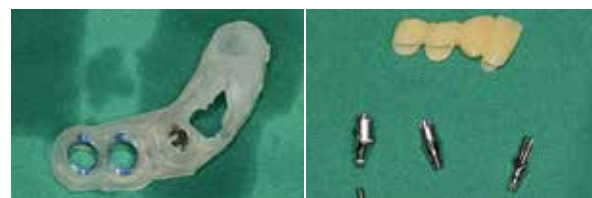As the plan had changed, 2nd surgery on the left side was done prior than the previous schedule.

2) Surgical Guide and Provisional Prosthesis :

Implant Studio can design surgical guide, temporary crowns and customized titanium abutments. They all can be prepared before surgery.



[Figure 13] Photos taken before the surgery




[Figure 14] Surgical Guide and Provisional Prosthesis

3) Drilling Protocol :

DIONavi. will output drilling protocol in the form of pdf file after the surgery has planned completely. You may print it out or you can just check it on your computer before the surgery. It contains the information of sleeve offset and the size of the implants.

Sleeve offset is sum of the gingiva depth and the length of sleeve. If you sum up the length of the implant and the offset, then you can get the drill length.



[Figure 15] Drilling Protocol

4) Placement of the Surgical Guide and Drilling :

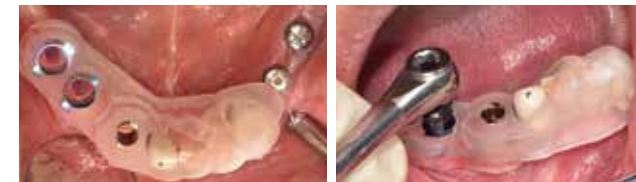Surgical guides made from DIONavi. always fit nicely without any additional fixations into the bone, as the guide is made from the accurate soft tissue model made from the oral scan data.

5) Placing the Implants :

The implants were inserted until the guide stop on the fixture driver met the sleeve. When the guide stop reaches metal sleeve, it means that the implant has placed at the right position.

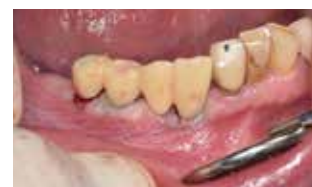6) Placing the Provisional Prosthesis :

After the surgery is done, provisional crowns with pre-fabricated customized abutments were seated. As the surgery went flapless, tissue damage was hardly seen.



[Figure 16] Placement of the Surgical Guide and Drilling

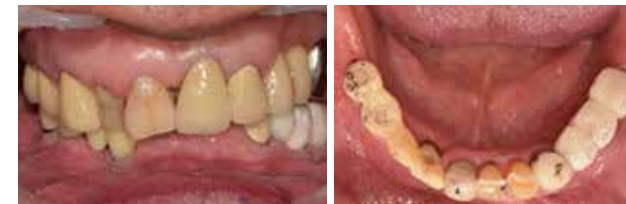[Figure 17] Placing the Implants



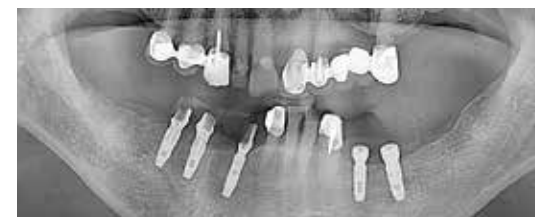[Figure 18] Placing the Provisional Prosthesis

7) Post-op Panoramic X-ray view and Photos :

Adjustment was minimal on provisional crowns on the right side. As the upper dentition worn badly, it was very hard to reproduce the anatomic features on the occlusal surface of crowns. Provisional crowns on the left side were made manually with stock abutments on.



[Figure 19] Post-op Panoramic X-ray view and Photos

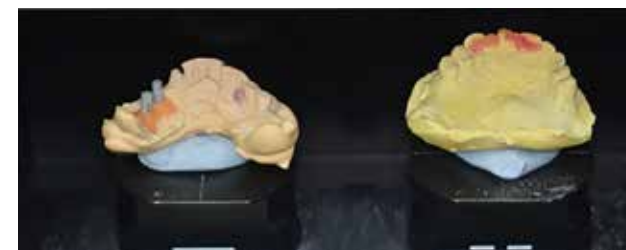


4. FINAL PROSTHESIS

After 2 months of waiting, it was started to make final prosthesis.



[Figure 20] Model scan with D2000 to make PMMA provisional crowns and customized Ti abutments on the left side



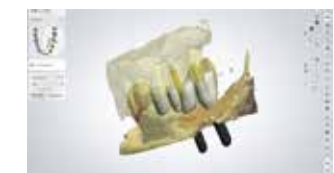The provisional crowns on both sides were severely worn out on the day he visited our office after 2 months. Due to the abrasion of crowns, the bite of this patient became unstable at that time. I delayed making final crowns, and decided to make provisional prosthesis including customized Ti abutments on the left side first, as the crowns on the right side were preserved better than left. This was intended to reestablish the occlusal relationship to help making final prosthesis easier.

Designing Ti Customized Abutments and PMMA Provisional Crowns :

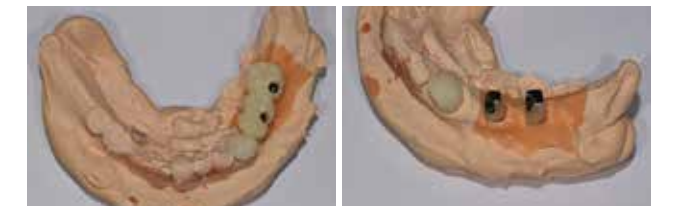
The cast models were scanned by D2000. D2000 has a texture scan function and it allows for dental technicians to distinguish gum rubber portion from stone model easily. And if there is something drawn on the stone model, D2000 will show it on the surface of the digital scan model too. This is very useful when you want to write something on the cast model, like a special request on the case or a margin line that should be drawn on the cast or anything that should be written on the cast.



[Figure 21] Designing Ti Customized Abutments and PMMA Provisional Crowns

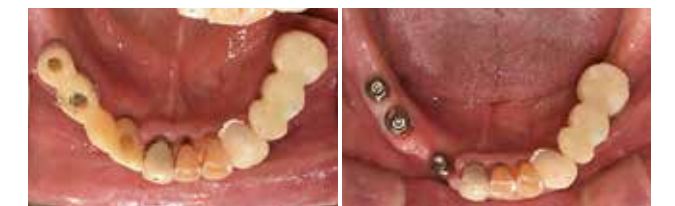

The holes over the PMMA crowns will act as a jig for the placement of customized abutments.



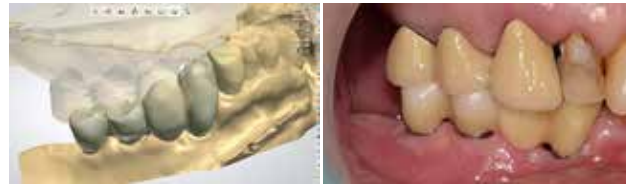[Figure 22] PMMA Provisional Crowns and Customized Ti Abutments on the Model

New PMMA crowns were seated on the left side. After removal of the PMMA crowns on the right side, an impression was taken. As the bite became more certain after seating new crowns on the left side, I decided to make full contour zirconia crowns for final prosthesis with the impression taken then. As seen in the right one of two pictures of figure 23, the soft tissue around abutments was secured nicely through the immediate loading period.



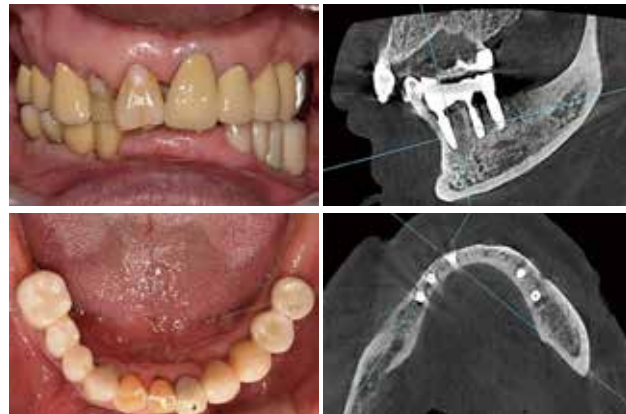
[Figure 23] After Seating the PMMA Crowns on the Left Side

Final crowns were nicely seated as they were designed for. Customized Ti abutments for temporary crowns were used for the final prosthesis again.

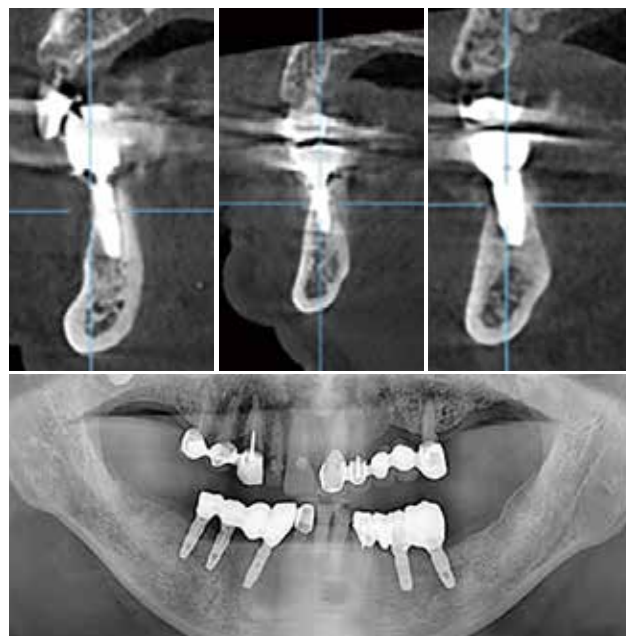


[Figure 24] Designing and Seating Full Contour Zirconia Crowns on the Right Side

CBCT shots and Panoramic X-ray view show that the implants are placed right at exact locations. Even after the 2 months of immediate loading period, marginal bone loss was not seen.



[Figure 25] Photos, CBCT, Panoramic X-ray View after Finishing the Treatment

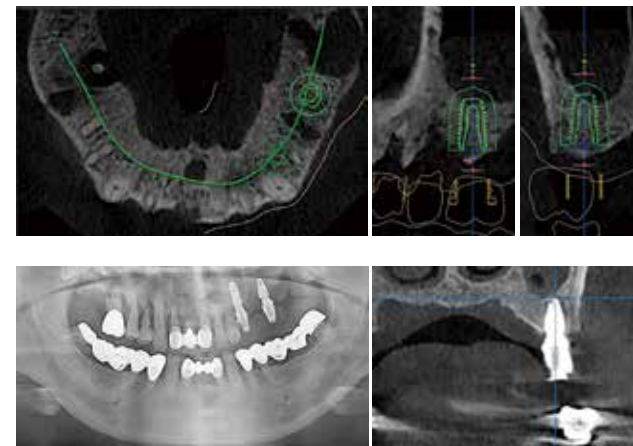


Benefit of DIONavi.

As this case shows, DIONavi. anticipates every aspect of the implant treatment prior to surgery. Due to the final aim of implant treatment lies in a perfect restoration of edentulous site, the implant surgery should be planned and done with delicate prosthetic strategy. In that sense, it can be said that DIONavi. is the most advanced and easiest way to achieve the real goal of implant treatment, because it helps dentists to plan surgery under prosthetic considerations in a very intuitive way.

With DIONavi. dentists can get prosthetic benefit from placing the implants at the right position for final prosthesis. It also helps to fabricate immediately loaded provisional prosthesis before surgery in cooperation with 3shape's versatile CAD program Dental Designer. This is a huge benefit for fully or partially edentulous patients who cannot eat anything without temporary prosthesis.

Besides the prosthetic advantage, It also gives surgical benefit through delicately planned surgical strategy. For example, you can avoid damaging the important anatomical features like, sinus cavity, nasal cavity or inferior alveolar nerve while surgery with help of the precisely planned drilling protocol of DIONavi. Additionally, with DIONavi. the whole surgery can be finished without flap reflection. This means patients will have less damage while surgery and from what I have experienced, patients love this, because they feel less pain and discomfort after the surgery has ended.



[Figure 26] Implants Placed Avoiding Sinus Cavity and Extraction Site by Delicately Planned Surgery with DIONavi.

- In short, DIONavi. gives benefit of
- 1.Real prosthesis leading surgery, assuring exact place and path of implants for final prosthesis
 - 2.Placing provisional prosthesis along with the placement of implants
 - 3.Avoidance from damaging important anatomic features, like Inferior Alveolar Nerve, Sinus Cavity
 - 4.Minimally invasive surgery without flap reflection

Epilogue

There might be still lots of dentists who think that they do not need a guide for their surgeries. Of course, it is true. However I want to make it clear that if a skilled oral surgeon meets DIONavi. he could improve his quality of treatments in both surgical and prosthetic aspects. It also supports dentists who are not familiar with implant surgeries. In brief, DIONavi. is a good friend of every dentist who practices implant treatment.

I highly recommend this innovative derivative from state of the art dental CAD/CAM technology to every dentist who does implant surgery. Your patients will like what they experience while their implant treatments, less blood, less pain, less discomfort from having provisional prosthesis on the day of surgery. Just give it a try and you'll love it!

Flapless Crestal Sinus Augmentation: Hydraulic Technique

Byung-Ho Choi

Department of Oral and Maxillofacial Surgery, Yonsei University
Wonju College of Medicine, Wonju, South Korea

Introduction

Optimization of maxillary sinus floor elevation protocols to achieve high implant success rates, minimize morbidity, shorten treatment periods, and simultaneous implant placement is a constant challenge for clinicians. In this sense, the author describes a flapless crestal sinus floor augmentation procedure using a hydraulic sinus elevation system. The minimally invasive flapless procedure significantly decreases postoperative discomfort and complications versus conventional open-flap surgery. In flapless crestal sinus augmentation surgery, both transcresal osteotomy and sinus membrane elevation are performed via the implant osteotomy site without visual or tactile control.¹ For this reason, computer-guided surgery is mandatory not just to guide drilling for implant placement but also to control the drill depth to the bony sinus floor. To achieve high success rates in the flapless crestal sinus augmentation procedure, membrane integrity is a primary condition for success. In order to keep the membrane integrity safely, it is necessary to improve the techniques and instruments. This chapter addresses the techniques and instruments for successful flapless crestal sinus floor augmentation, using a hydraulic sinus elevation system combined with computer-guided implant surgery.

Surgical Instruments

- 1) Osteotomy drill
- 2) Dome-shaped crestal approach bur
- 3) Hydraulic membrane lifter
- 4) Bone plugger, sinus curette
- 5) Stopper
- 6) Digital surgical guide

1) Osteotomy drill

This drill is used to drill to 1 mm short of the sinus floor. It comes with various lengths and diameters having the stop feature. The surgical guide guides the drill's depth, direction and position.

2) Dome-shaped crestal approach bur

This bur is used to eliminate the remaining bone below the sinus floor (Fig 1). The bur has round tip and vertical stop. The tip of the drill is characterized by a smooth cutting blade. This shape helps to avoid direct damage even if it comes in direct contact with the sinus membrane. The dome-shape also makes it safe to be used in either flat or steep bone walls. The bur also has a stop feature to control the drill depth through the surgical guide. To help control the drill depth precisely, a number of different stopper lengths are available.

Using the stop feature and the stoppers, the drill depth can be controlled



Fig. 1. Dome-shaped crestal approach burs.

within 1mm range. The dome-shaped crestal approach bur has 3.2-mm-diameter, which is smaller than the diameter of implants placed in the maxillary premolar (Ø4.0mm) and molar (Ø5.0mm).

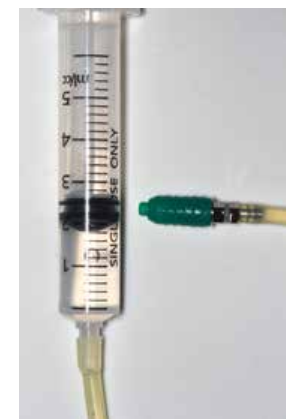

Fig. 2. Hydraulic membrane lifter

3) Hydraulic membrane lifter

This is for injecting liquid into the maxillary sinus. It is comprised of a syringe, tube and a nozzle (Fig 2).

Tip of the nozzle has a feature that can completely close the opening to the drill hole. Thus, it has a conical-shaped sealing part and an extension part that is inserted into the drill hole. The other end of the nozzle is connected with the tube, which is then connected to the saline-filled syringe. The nozzle also has a handle feature (Fig 3). The handle not only helps the nozzle be



Fig. 3. Nozzle with handle

positioned into the hole and secured in place but it also helps the nozzle to pressure the opening area. The syringe should be a 5-ml disposable syringe. A 1-ml syringe is too tiny to apply enough pressure. In addition, if the extension part of the syringe that connects the tube to the syringe is too short, the tube can be easily separated when applying pressure. Therefore, if possible, use a syringe with an elongated connection part.

4) Bone plugger, sinus curette

Bone plugger is used to insert bone-grafting material into the sinus cavity through the drill hole. Sinus curette is used to then disperse this bone-grafting material in the sinus cavity (Fig 4). They have a stop



Fig. 4. Bone plugger and sinus curette

feature to control the depth of insertion into the sinus cavity. Their diameters is Ø2.6mm, which will allow it to go into the Ø3.2mm hole created by the 3.2-mm-diameter, dome-shaped crestal approach bur. The head of the sinus curette has a dome-shape.



Fig. 5. Stoppers

5) Stopper

Stopper is designed to be able to connect to any of the crestal approach bur, bone plugger or sinus curette. It also comes in varying lengths, which can help control the depth of insertion into the sinus cavity within 1mm range (Fig 5).

6) Digital surgical guide

Surgical guide guides the depth and direction of the osteotomy drill, crestal approach bur and the implant. Therefore, a highly accurate and precise surgical guide must be used – recommended the vertical error value should be less than 0.5mm. From the author's experiments, the average vertical error value of 0.44mm was achieved if the surgical guide was digitally designed using both the CBCT image and the oral scan image taken by TRIOS (3Shape, Copenhagen, Denmark) and produced using a 3D printer. The error from the digital surgical guide might have resulted from each step of the surgical guide production including the digital impression step, the fusion of the surface scan image with the CBCT scan image, and the 3D printing process. The error value increases if the surgical guide is made with the use of stone models from alginate impressions instead of the digital impressions. If the vertical error value of surgical guide is greater than 1mm, the risk of membrane perforation increases.

Technique

Preoperative Protocol

The best location to penetrate the bony sinus floor is determined with the help of CBCT image of the maxillary sinus while taking into consideration both the position of the final prosthesis and the anatomy of the maxillary sinus, such as the shapes of the sinus walls

as well as the presence of the septum. This location will be where the implant is placed. Once the location has been determined, the drilling

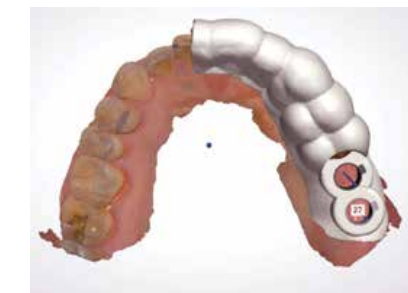

Fig. 6. Digital surgical guide designed

depth is calculated. This is important as to avoid causing membrane perforation while drilling. CBCT's cross-sectional image can help define the length of the osteotomy up to the sinus floor. A panoramic 2D image or dental X-rays is not appropriate for this purpose as they are not precise enough. In

contrast, a CBCT image can show the anatomy of the maxillary sinus with great precision in 3D. CBCT scans and oral digital impressions are used to perform three-dimensional implant planning and to create a customized surgical guide (Fig 6). If immediate restoration is being performed, the customized abutment and provisional restoration is designed and then made using the CAD/CAM milling machine. When designing the customized abutment and crown, one must consider the factors such as soft tissue profile around the proposed location of the implant and the relationship between the implant with its adjacent and opposite teeth respectively using the dental design software (Dental System, 3shape, Copenhagen, Denmark). The surgical guide, prefabricated customized abutment and crown are prepared before implant surgery.

Surgical Protocol

1) Drill osteotomy

Under local anesthesia with 2% lidocaine, the stereolithographic surgical guide is placed in the mouth and checked for proper seating. The guide should be positioned accurately and securely. The accurate position of the guide is extremely important for precise implant placement because minor deviations can lead to errors in drilling and implant placement. The tissue punch is the first drill in

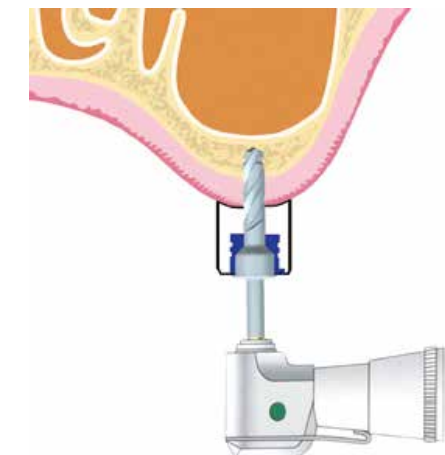


Fig. 7. Drilling to 1 mm short of the sinus floor

sequence. The soft tissue of the proposed implant site is punched through the guide with a 3-mm soft tissue punch. After punching the soft tissue, the crestal bone is flattened with a bone-flattening drill. After flattening the bone surface, implant osteotomy is prepared to 1 mm short of the sinus floor (Fig 7). The drilling is performed using sequential drills with increasing diameters through the guide. The implant osteotomy is prepared to the appropriate final diameter according to the drill sequence. The drilling depth is controlled by the drill stop in the shank that corresponds to the sum of the implant length, the gap between the guiding sleeve and the implant, and the guiding sleeve height (Fig 8). The drill stop precludes the drill from going deeper than intended. Final drill should be about 0.7 – 1.0 mm smaller in diameter than that of the implant. For example, if Ø5.0mm implant is to be placed, use up to Ø4.3mm drill.

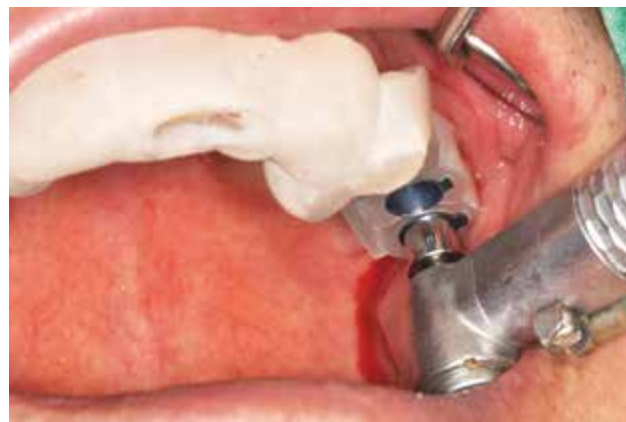

Fig. 8. Drilling through the surgical guide

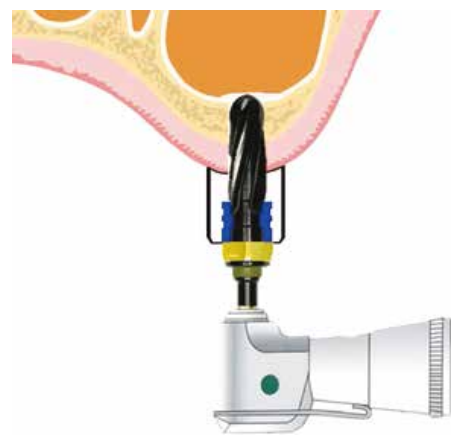


Fig. 9. Dome-shaped crestal approach drill eliminating the remaining bone below the sinus floor

2) Penetrating the bony sinus floor:

After drilling to 1 mm short of the sinus floor, a 3.2-mm-diameter, dome-shaped crestal approach bur is used to eliminate the remaining bone below the sinus floor (Fig 9). After removing the

remaining 1mm, the bur is advanced into the sinus cavity using the bur with the stop that allows it to drill down another 1mm and expand the opening on the sinus floor. The bur is used at a speed of < 10 rpm. During the drilling, upward force is applied to drill into the bony sinus floor, thus pushing the drill 1 mm beyond the sinus floor, which is controlled with drill stops and surgical guides. The bony sinus floor is perforated rather than fractured. The low-speed drilling leads to decreased friction between the bur and the membrane, when the bur comes into contact with the membrane. As a result, the technique reduces the risk of impinging on the sinus membrane attributable to the risk of subsequent membrane perforation. If the bur has no stop, stopping the drill manually at the moment of penetrating the last bone layer will come too late and the drill will still push forward and get very abruptly drawn into the sinus cavity. This explains why this maneuver risks perforating the sinus membrane. The dome shape of the crestal burs, the low-speed drilling with upward force and the perfect drilling depth control might be crucial to remove the cortical bone of the sinus floor.

3) Membrane elevation

After puncturing the sinus floor, the most reliable method should be used to elevate the Schneiderian membrane without injuring it. The most reliable one is to elevate the sinus membrane using a hydrostatic pressure because the pressure exerted is uniformly distributed across the sinus membrane to minimize membrane tearing during membrane elevation.^{2,3} Compared to other techniques, the hydraulic pressure generated by injecting saline into the drill hole offers the most uniform distribution of forces, resulting in uniform elevation of the sinus membrane.

The step for membrane elevation is done without the surgical guide. First, the hydraulic membrane lifter's nozzle is connected with the handle, and then the nozzle is positioned into the opening of the drill hole and secured in place. And then 0.8mL of saline is slowly injected to separate the sinus membrane from the bony sinus floor and to push the membrane upward (Fig 10). Approximately the first 0.3 – 0.4 mL will go into the drill hole without feeling pressure. As the saline enters through the hole and touches the sinus membrane,

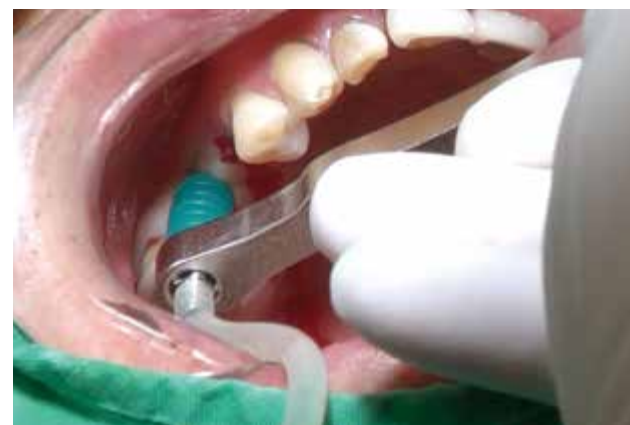

Fig. 10. Nozzle positioned into the transcrestal osteotomy canal and secured in place

the membrane is elevated with feeling pressure. However, as soon as the membrane is elevated, the pressure is decreased. It is important not to inject too much saline as the pressure decrease as it can elevate the sinus membrane far too much. Therefore, saline should be slowly injected 0.1 ml at a time (Fig 11). If the sinus floor has not been fully penetrated, the pressure can be felt after injecting 0.3 – 0.4 ml of saline but no more saline can be injected. In which case, another attempt should be tried to re-inject saline after drilling an additional 1mm into the sinus cavity using the 3.2-mm-diameter, dome-shaped crestal approach bur.

4) Membrane integrity test

The most reliable way to test the membrane integrity is the aspiration technique. The membrane integrity is evaluated by drawing the saline back through the drill hole. The volume of the saline that was injected is fully retrieved, suggesting that the membrane remains intact. Directly viewing the exploration, using the Valsava procedure, and probing or irrigation does not guarantee

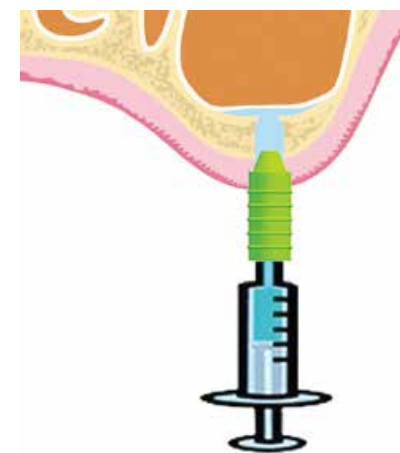


Fig. 11. Injecting 0.8-ml of saline to separate the sinus membrane from the sinus floor and push the membrane upward.

the preservation of the sinus membrane. In the author's view, retrieving and measuring the injected saline back through the drill hole is the best test to guarantee membrane integrity.

Sinus membrane perforation is tested immediately after elevating the sinus membrane. Once 0.8mL of saline is injected to elevate the sinus membrane, the same syringe is used to suck back the saline. If all the saline that was just injected is sucked back up and syringe shows negative pressure, then the membrane has not been perforated. There will be some blood and bubbles that get sucked up with the saline. This is because the air that was in the hole can be pushed in with the saline and some bleeding can occur as the membrane is separated from the bone. The sinus membrane is perforated if only part of the saline is sucked back up and syringe is unable to achieve negative air pressure. If this is the case, do not place bone-grafting material into the sinus cavity. It is possible that mucus can penetrate into the graft through the perforation site

and affect negatively the bone formation after surgery. In addition, bone-graft can escape into the sinus cavity through the perforated area, causing sinus inflammation. If the membrane is perforated during the membrane elevation procedure, the surgery should be attempted again after about two months. During the re-attempt, the surgery is tried from a different area, away from the sinus membrane that was damaged for a better success rate.

5) Expanding opening hole of the sinus floor

Prior to inserting grating material into the maxillary sinus, the opening hole of the sinus floor into the sinus cavity is expanded. The surgical guide is re-placed in the mouth and using the 3.2-mm-diameter, dome-shaped crestal approach bur, the hole is expanded by advancing it further 1mm into the sinus cavity (Fig 12). The bur should be advanced precisely 1mm into the sinus cavity using the

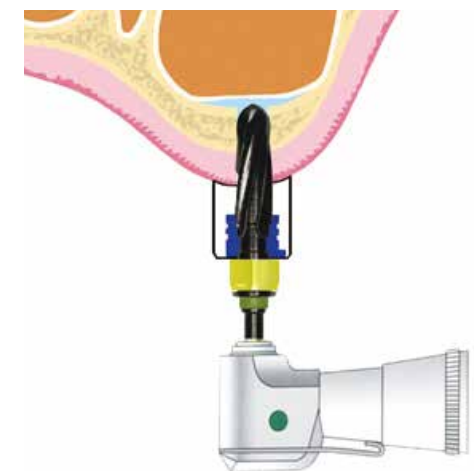

Fig. 12. Dom-shaped crestal approach drill pushed 1mm beyond the sinus floor

surgical guide and stop on the bur. After that, the surgical guide is removed and the bone plugger is inserted to check for presence of any other bony barriers inside the hole – making sure the opening is completely clear. The bone plugger should be restricted not to insert into the sinus cavity further than the additional 1 mm using a stopper.

6) Grafting procedure

The bone grafting procedure is performed without the aid of a surgical guide. If Bio-Oss collagen sponge (Geistlich Pharma AG, Wolhusen, Switzerland) is used as graft material, a 1-cm³ of the sponge is cut into nine pieces and then inserted into the sinus cavity through the drill hole using the bone plugger. When inserted into the sinus cavity, the grafting material has a tendency to remain pushed upwards. Therefore, it is necessary to spread the material in the sinus cavity. Whenever approximately 0.2 – 0.3ml of grafting material is inserted, it is dispersed using a sinus curette. The way of dispersing it is to rotate the sinus curette in the sinus cavity,

both clockwise and anti-clockwise, drawing largest circle possible (Fig 13). The amount of grafting material inserted is determined by the height of membrane elevation. When attempting to elevate the membrane by 3 mm, insert 0.3 ml; elevate by 5mm, insert 0.5

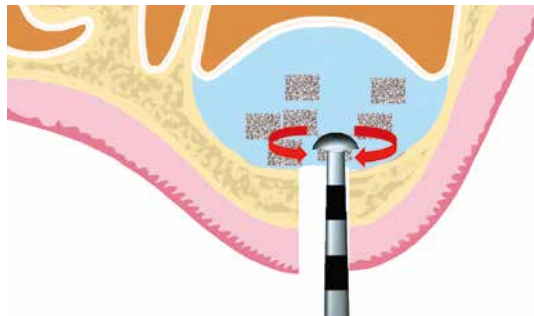


Fig. 13. Sinus curette used to spread the graft material

ml; elevate by 7 mm, insert 0.7 ml. If only the grafting material is inserted into the sinus cavity without placing implants, an additional 0.3 ml is inserted. For example, when attempting to elevate by 7mm, 1 ml of graft material is inserted.

7) Implant placement

Simultaneous implant placement is conducted. Before implant placement, the final drilling is performed 1mm beyond the sinus floor through the surgical guide to enlarge the sinus floor. Implants are then placed in the formed socket through the guide. It is recommended that implant be placed simultaneously with the grafting procedure because the implant will help disperse the grafting material as well as help keep the membrane elevated. However, if the vertical height of the residual bone is less than 2mm and the implant has no primary stability, only the bone-grafting material is inserted into the sinus cavity without placing implants. Implant stability is evaluated by resistance of the implant during insertion and via measurement of the implant's insertion torque.

8) Immediate restoration or installing healing abutment

Immediate restoration is performed using the customized abutment and preliminary restoration that were prefabricated pre-surgery if the following conditions have been met (Fig 14): the vertical height of the residual bone is greater than

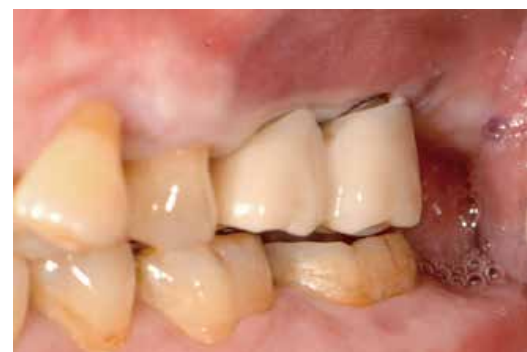

Fig. 14. Immediate restoration with prefabricated customized permanent abutments and resin temporary crowns. The occlusion and articulation of the crowns were adjusted out of contact with the opposing teeth

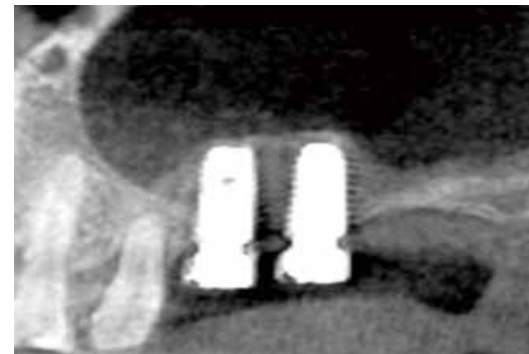


Fig. 15. Healing abutment is installed if the implant is unable to secure the primary stabilization.

4mm, the implant has achieved good primary stability and it has splinted with neighboring implants. For a single implant, immediate restoration is performed if the primary stability is greater than 30Ncm. The restoration process must follow the immediate nonfunctional loading concept by adjusting the crown to avoid contact with the opposing teeth. Patients are asked to refrain from using the restored teeth for the 3-4 months. A cover screw or healing abutment is installed if the implant is unable to secure the primary stabilization. (Fig 15)

9) Radiographic evaluation

The patients are scanned postoperatively with the CBCT unit to inspect and identify any sinus membrane perforations.

Advantages

Compared to a lateral approach, the flapless crestal approach offers many advantages. Pain, discomfort and healing time are greatly reduced because of the absence of trauma resulting from the large sinus floor incisions that are used in lateral sinus elevation surgeries.^{4,5} The flapless crestal approach preserves the integrity of the bony sinus structure, except at the implant site. In addition, this is a scarless procedure, which is the result of using the punch incisions and simultaneous implant placement with the transmucosal components. The flapless crestal approach eliminates the need for a second surgical procedure to connect the transmucosal components, thereby reducing chair time. The aesthetic results are also improved compared to the lateral approach. Based on the author's experience, the average operative time for the flapless crestal approach was 17 ± 15 minutes. The surgical procedure substantially decreased the length of the surgery, compared to the previous crestal approaches. Some possible reasons for this shortened operative time might be due to using

drills with stops, using surgical guides, the effective membrane elevation system, eliminating the need for sutures, and avoiding soft tissue elevation. In addition to a short operative time, the approach is successful in anatomically difficult sinus structures. During the sinus lift surgery, problems are not encountered in the presence of antral septa or when drilling along a steep bone walls. Therefore, this procedure can be highly successful in patients with septated maxillary sinuses.

In patients with antral septum

Presence of antral septum in the sinus cavity poses an additional difficulty in a lateral approach. As a result, the lateral approach requires greater skill of the surgeon and longer operative time. Even surgeons with a lot of experience often cause sinus membrane perforation. However, with the aid of a surgical guide and hydraulic

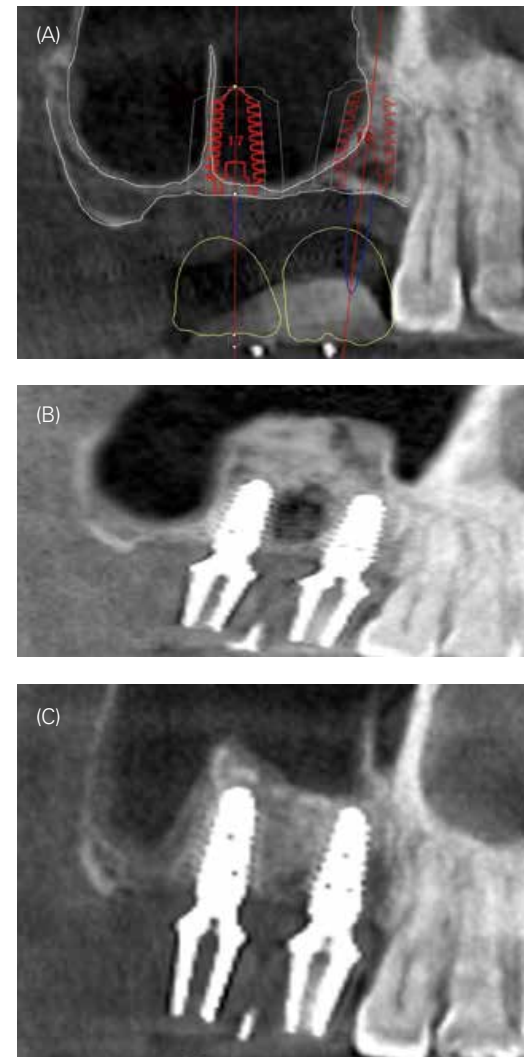


Fig. 16. A case with antral septa. Before (A), immediately (B) and 6 months (C) after surgery

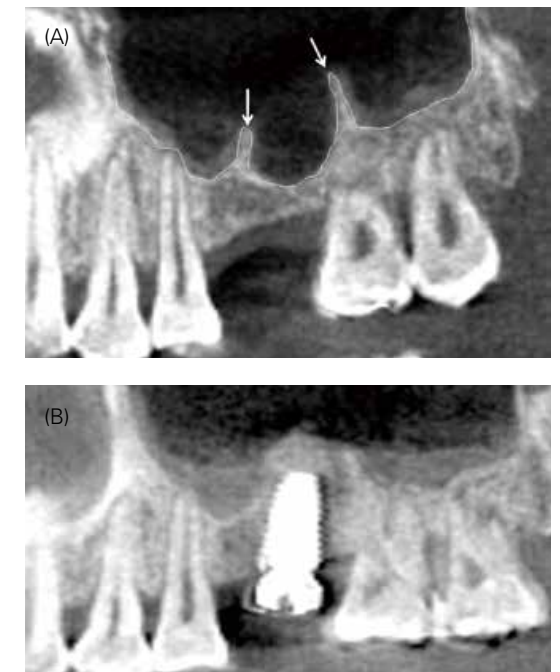


Fig 17. A case with antral septa. Before (A) and 6 months (B) after surgery

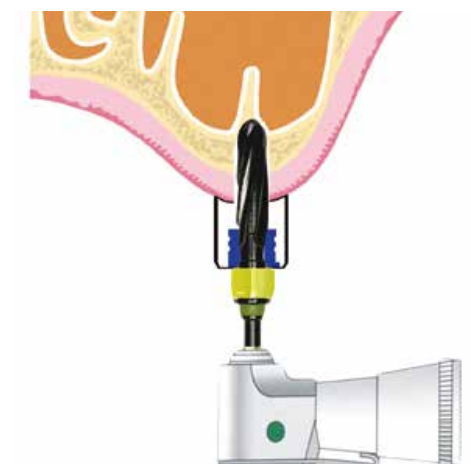

Fig 18. Dome-shaped crestal approach bur under the septum

pressure, the flapless crestal approach makes the procedure simpler and faster (Fig 16). The septum can actually be utilized to aid in shaping grafting material in the maxillary sinus (Fig 17). One of the reasons for high success in patients with septated maxillary sinuses is that the dome-shaped crestal approach bur, which is used to drill through the sinus floor, can be safely used in steep bone walls as well (Fig 18). Due to its round shape, the drill works whether the surface is flat or not. Bone in the septum area tends to be hard, which can help implants achieve primary stability. If the pre-surgery CBCT scan reveals presence of a septum, the surgeon must take this into consideration in determining the appropriate position and

depth of initial drilling. When drilling through a steep sinus wall, depending on the angle, the surgeon may need to drill an additional 1mm compared to when drilling through a flat wall.

- In patients with severely atrophic maxillae

Even in patients with severely atrophic maxillae (1 to 2 mm of residual bone), the implants can be successfully inserted at the same time as maxillary sinus elevation (Fig 19).⁶ Typically in these situations, maxillary sinus floor wall has hardened cortical bone remaining. To place implants successfully in 1 to 2 mm of bone in the posterior maxilla, the residual bone quality should be effectively used to achieve primary implant stability in the patients. The drilling and implant placement is performed without shaking their axis with the aid of surgical guide. Tapered implants are used. The osteotomy for implant placement is enlarged to 0.7 - 1.0 mm narrower than the anticipated implant diameter

- Grafting material

It is difficult to create a desirable shape of grafting material in the sinus cavity through the flapless crestal approach because the material is inserted without the ability to see inside the sinus cavity. The goal of grafting procedure using the flapless crestal approach

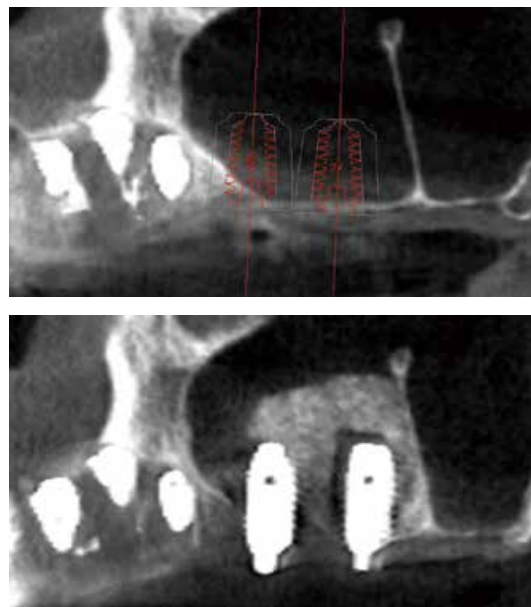


Fig. 19. CBCT scans of the severely atrophic ridge with 1mm of residual bone before (A) and after (B) surgery.

is to simply maintain the space created by the sinus membrane elevation. In other words, keeping sinus membrane elevated to encourage new bone formation underneath the membrane. The elevated sinus membrane can act like a tent while providing rich flow of blood and take advantage of its bone regeneration ability. The environment of the sinus cavity below the lifted sinus membrane after sinus membrane elevation is quite beneficial for

bone formation.^{7,8} This is in part because the cavity is surrounded by bone, and the primary source of revascularization of the graft originates from the adjacent bony walls. In addition, the sinus membrane has an intensely vascular network and contains mesenchymal progenitor cells and the cells committed to the osteogenic lineage.⁹ The periosteum of the lifted sinus membrane is another source of bone forming-cells. Accordingly, new bone formation in the newly created space can be induced by elevating the sinus membrane alone provided that the space is well-maintained. When implant is placed along with grating material, both the implant and the graft material can help maintain the elevated sinus membrane. The graft material for the flapless crestal approach must be selected on the basis of: its ability to maintain space, ability to be inserted through a small opening and ease of dispersion inside the sinus cavity.

The graft material can be in either particle, gel or sponge in form. The particle type can be pushed into the sinus cavity through the drill hole using a bone carrier. However, this type can be ineffective and more time-consuming as the small opening makes it difficult for the particles to be pushed in.

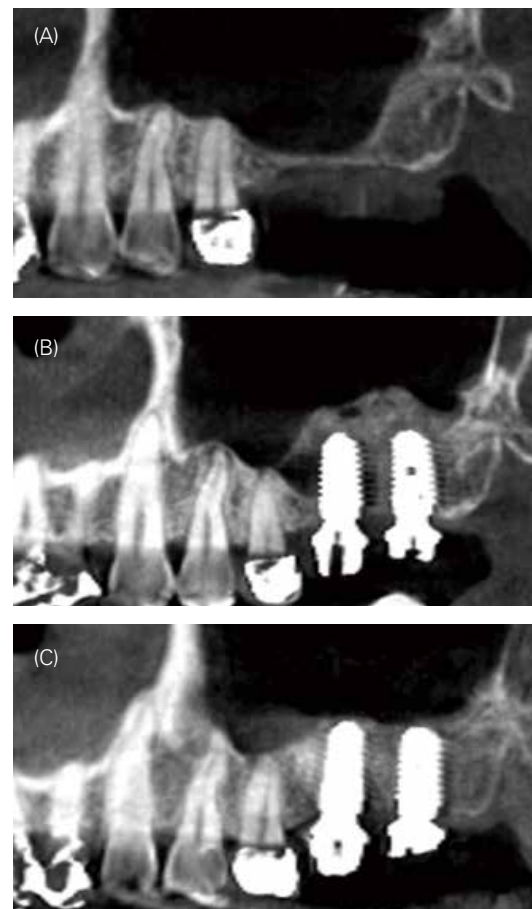


Fig 20. CBCT scans taken before (A), immediately (B), and six months (C) after surgery

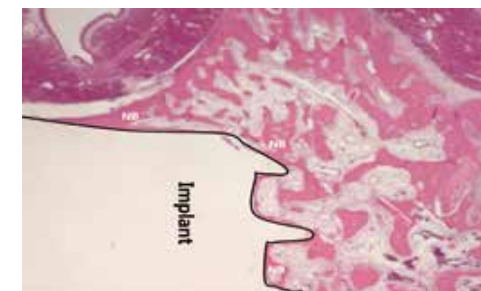
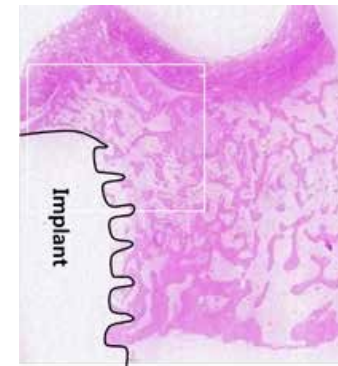


Fig 21. View of the specimen of Bio-Oss collagen sponge. A: Low-ratio. B: High-ratio

Advantage for the gel type is that it can be injected into the sinus cavity through the drill hole using a syringe. However, its disadvantage is that if there is space inside the sinus cavity, the gel can shift around. In particular, in a laid-down position, the gel moves towards the back. If a thermo-sensitive gel is used instead, the gel may be able to solidify inside the sinus cavity and hold its shape. If the gel and particle types are mixed together, two things can happen. Firstly, if the ratio of particle type is greater than gel type, the mixture might not be able to be injected using a syringe. Secondly, if the ratio of particle type is less than gel type, the mixture may be absorbed too easily. In contrast, if sponge type material is inserted into the sinus cavity as grafting material, the sponge can protect the membrane from the roughness of graft material and may minimize membrane tearing during the grafting procedure. The sponge type material is soft and more elastic, which makes it easier to handle. It can be cut into a size that can easily be pushed through the hole and when positioned, the sponge is able to maintain its space under the elevated sinus membrane. Bio-Oss collagen sponge (Geistlich Pharma AG, Wolhusen, Switzerland) is a commonly used sponge-type grafting material. Bio-Oss collagen sponge is made up of 90% cancellous bone from calf and 10% collagen from pig. Collagen sponge may not be suitable for maintaining space because it can be absorbed quickly. However, the Bio-Oss collagen is suitable because Bio-Oss bone particles are able to maintain its shape without being absorbed too quickly when inside the sinus cavity (Fig 20). The author's animal experiment showed that when Bio-Oss collagen sponge was used as graft material for bone augmentation in the maxillary sinus, bone formation in the graft site was excellent and the mean osseointegration rate was more than 65 % (Fig 21).

Summary

The first key factor for the success of flapless crestal sinus augmentation is penetrating the bony sinus floor using the dome-shaped crestal approach bur, the low-speed drilling with upward force and the perfect drilling depth control. The drilling depth is controlled within 1mm range. The second factor is that the hydraulic pressure is used to safely elevate the sinus membrane and check for membrane integrity. The third factor is that CBCT scan with high resolution, advanced surgical equipment and highly precise surgical guide are used for the surgery.

References

1. Toffler M: Minimally invasive sinus floor elevation procedures for simultaneous and staged implant placement. *N Y State Dent J* 70:38-44, 2004.
2. Chen I, Cha J. An 8-year retrospective study: 1,100 patients receiving 1,557 implants using the minimally invasive hydraulic sinus condensing technique. *J Periodontol* 76:482-491, 2005.
3. Kao DW, DeHaven HA. Controlled hydrostatic sinus elevation: a novel method of elevating the sinus membrane. *Implant Dent* 2011;20:425-429.
4. Fortin T, Bosson JL, Isidori M, Blanchet E: Effect of flapless surgery on pain experienced in implant placement using an image-guided system. *Int J Oral Maxillofac Implants* 2006;21:298-304.
5. Nkenke E, Eitner S, Radespiel-Troeger M, Vairaktaris E, Neukam FW, Fenner M: Patient-centred outcomes comparing transmucosal implant placement with an open approach in the maxilla: A prospective, non-randomized pilot study. *Clin Oral Implants Res* 2007;18:197-203.
6. Peleg M, Mazor Z, Chaushu G, Garg AK: Sinus floor augmentation with simultaneous implant placement in the severely atrophic maxilla. *Periodontol* 1998;69:1397-1403.
7. Lundgren S, Andersson S, Gualini F, Sennerby L. Bone reformation with sinus membrane elevation: a new surgical technique for maxillary sinus floor augmentation. *Clin Implant Dent Relat Res* 2004;6:165-173.
8. Palma VC, Magro-Filho O, Oliveira JA, Lundgren S, Salata LA, Sennerby L. Bone reformation and implant integration following maxillary sinus membran elevation: an experimental study in primates. *Clin Implant Dent Relat Res* 2006;8:11-24.
9. Gruber R, Kandler B, Fürst G, Fischer MB, Watzek G. Porcine sinus mucosa holds cells that respond to bone morphogenetic protein BMP-6 and BMP-7 with increased osteogenic differentiation in vitro. *Clin Oral Implants Res* 2004;15:575-580.

DIONavi. Clinical Review

Dr. Lee Hyang Reon, Clinical Director Michigan Dental Clinic

Minimally invasive (flapless) extraction accompanied by immediate implant placement and bone graft.

The discussion for immediate implant placement after tooth extraction still appears to be in progress. The most problematic area for immediate implant placement after tooth extraction procedure is drill slippage. Unlike other guides, using DIONavi Surgical Guide removes the risk of slippage and is very helpful in placing implants accurately at the desired location. In addition, Flapless Surgery which minimizes trauma inflicted on the patient is an advantage.

Dr. Dong Do Eun, Clinical Director Welcome Dental Clinic

Overcoming the obstacles of the anterior maxilla implant placement through pre-planning.

The biggest advantage of DIONavi is the "Power of diagnosis". Biggest concern for an implant procedure is the difficulty of knowing the the best fixture direction, depth and length during the surgery. However after introducing DIONavi, sufficient planning and analysis can be done in advance of implant surgery and including bone graft and connective tissue graft. Especially in the anterior maxilla, for many cases there is difficulty in maintaining a safe and secure path through access hole to Buccal Bone and Cingulum. However, by using DIONavi and following the existing treatment plan, surgery can be done accurately and obstacles overcome.

Dr. Kim Sang Ha, Clinical Director e-Wellness Dental Clinic

Stable Implant Placement in the Edentulous Case Using DIONavi Surgical Guide System

Major concerns in edentulous cases are how to fix the surgical guide and while using the flapless technique, how to overcome sharp adjustments that may occur. To solve this issue, Surgical Guide Fix and Fix Pin were used to fix the Guide for stable implant placement. As for Flapless Technique, the trimming of the bone plane is not an easy task. However, with DIONavi, use of the Bone Flattening Drill allows for flattening the drilling area for accurate subsequent drilling without risk of slippage. This advantage of DIONavi offers high satisfaction to the surgeon. Also in general for cases where mental foramen is positioned relatively forward, traditional implant procedures can be difficult. However, with DIONavi implants can be precisely placed at the desired site following a pre-designed treatment plan that removes the patient's biggest anatomical risk factors and also gives the surgeon the peace of mind.

Dr. Choi Sung Ok, Clinical Director Apple Tree Dental Hospital

Sinus Lift Surgery Using DIONavi and Water Pressure

DIONavi surgery, as opposed to conventional implant surgery, has no incision and closure process thus, surgical procedure is short and results in very high patient satisfaction. In particular, sinus elevation procedure can be simple and reliable through the Crestal Approach Technique using water pressure. Specifically, depth control from Sinus Drill Stopper and the rounded shape of the Sinus Drill end minimizes damage to the sinus membrane. For cases requiring Lateral Approach Technique, to minimize patient's discomfort and faster healing, DIONavi is used for sinus elevation.

DIO IMPLANT

66, CentumSeo-ro, Haeundae-gu, Busan, 612-020, Korea

T. +82.51.745.7777 F. +82.51.745.7778

www.dionavi.com



www.dionavi.com